

Open Tibial Shaft Fractures: II. Definitive Management and Limb Salvage

J. Stuart Melvin, MD
Derek G. Dombroski, MD
Jesse T. Torbert, MD
Stephen J. Kovach, MD
John L. Esterhai, MD
Samir Mehta, MD

Abstract

Definitive treatment of open fractures of the tibial diaphysis is challenging. The high-energy nature of these fractures, as well as the contamination of the fracture site and devitalization of the soft-tissue envelope, greatly increases the risk of infection, nonunion, and wound complications. The goals of definitive treatment include wound coverage or closure; prevention of infection; restoration of length, alignment, rotation, and stability; fracture healing; and return of function. Advances in orthobiologics, modern plastic surgical techniques, and fracture stabilization methods, most notably locked intramedullary nailing, have led to improved prognosis for functional recovery and limb salvage. Despite improved union and limb salvage rates, the prognosis for severe type III open fracture of the tibial shaft remains guarded, and outcomes are often determined by patient psychosocial variables.

Despite modern soft-tissue management techniques and the greater number of implant options, good clinical outcomes following open tibial shaft fractures can be difficult to achieve. Fracture site contamination and destruction of the soft-tissue envelope increase the risk of complications. The goals of definitive treatment include timely wound coverage or closure; prevention of infection; restoration of limb length, alignment, rotation, and stability; fracture healing; and return of function. Advances in fracture stabilization, orthobiologics, and plastic surgical techniques have led to an improved prognosis for functional recovery and limb salvage. Even with these improvements, however, the prognosis for severe type III open fractures of the tibial shaft remains poor. Outcomes are often determined by patient psychosocial variables.

Fracture Stabilization

Early stabilization of open fractures of the tibial shaft is important for controlling pain, protecting the soft tissues from further damage, and providing for early mobilization. Historically, early attempts at stabilization centered on casting and were associated with infection rates >15% and malunion rates of up to 70%.¹ More recently, improvements in plating techniques, external fixation, and intramedullary (IM) nailing have resulted in better outcomes compared with casting. The treatment algorithm for open tibial shaft fractures appears on page 15 of part 1 of this article, “Open Tibial Shaft Fractures: I. Evaluation and Initial Wound Management,” which appears in the January 2010 issue of the *Journal of the American Academy of Orthopaedic Surgeons*.

From the Department of Orthopaedic Surgery (Dr. Melvin, Dr. Dombroski, Dr. Torbert, and Dr. Esterhai), the Division of Plastic Surgery (Dr. Kovach), and the Orthopaedic Trauma and Fracture Service (Dr. Mehta), the University of Pennsylvania, Philadelphia, PA.

J Am Acad Orthop Surg 2010;18:108-117

Copyright 2010 by the American Academy of Orthopaedic Surgeons.

Plate Fixation

Open reduction and internal fixation of open tibial shaft fractures with plates and screws has fallen out of favor because of concerns regarding potential damage to the periosteal blood supply and the high rates of complications, especially infection and exposed hardware. Bach and Hansen² reported severe osteomyelitis in 19% and hardware failure in 12% of Gustilo type II and III open tibia fractures managed with plate osteosynthesis. In a larger series of 97 open tibial fractures, Clifford et al³ reported a significantly higher rate of infection in type III open fractures (44.4%) compared with type I and II open fractures (5.4% and 7.8%, respectively). Although newer plating techniques, particularly minimally invasive plate osteosynthesis, seem promising because of the capability to limit iatrogenic soft-tissue damage, no study has yet evaluated these newer techniques in the treatment of open fractures of the tibial shaft. Further studies demonstrating lower complication rates are needed before plate osteosynthesis can be routinely advocated in the treatment of open fractures of the tibial shaft.

Although plate fixation has only a limited role in the definitive management of open tibial shaft fractures, plate stabilization has proved to be useful in a temporary capacity. Provisional stabilization of open tibial shaft fractures with a 3.5-mm limited-contact dynamic compression plate placed through the traumatic wound and secured with unicortical screws is useful in maintaining reduction during insertion of an IM nail.⁴ The plate is removed after the IM nail is locked. This tech-

nique is particularly useful for surgeons who are operating with limited intraoperative assistance.

External Fixation

The high complication rates associated with casting and internal fixation led to the use of external fixation as a treatment option for open fractures of the tibial shaft. External fixation offered two advantages over internal fixation. First, it enabled rapid fracture stabilization. Second, the lack of hardware implantation at the site of the open injury limited further soft-tissue damage. Typically, for diaphyseal fractures, external fixation frames consisted of simple half-pin and bar constructs in a uniplanar geometry. The authors of a recent meta-analysis reported a union rate of 94% at a mean of 37 weeks and an overall infection rate of 16.2% with external fixation.⁵ Chronic osteomyelitis reportedly developed in 4.2% of fractures. Alternatively, circular fixation (ie, skinny-wire fixation) can be used for acute and definitive management of open tibial shaft fractures. However, circular fixation more commonly has been used for reconstruction of open tibial shaft fractures associated with bone loss or infection.⁶

Despite acceptable union rates, high rates of complications have plagued most series, most commonly as the result of pin loosening, pin-tract infection, and malunion.^{5,7} Pin loosening and hardware failure have been associated with utilization of external fixation >3 to 6 months.⁷ This is a common problem with Gustilo type IIIB fractures, which often require >3 months to achieve union. Pin-tract infection occurs in up to 32% of patients and can lead

to chronic osteomyelitis and complicate the conversion to IM nailing.⁵ Predrilling should be done to minimize thermal necrosis of cortical bone because it may reduce the incidence of pin loosening and infection.⁷ Reducing the amount of time spent in external fixation through early conversion to IM nailing is a useful technique for lowering infection rates.⁸

Intramedullary Nailing

IM nailing is a safe, effective method of stabilization for open tibial shaft fractures. This technique offers biomechanically superior fixation that maintains length, alignment, and rotation through static interlocking. It also allows for early weight bearing and adjacent joint motion.

A recent review of the literature on the treatment of open tibia fractures found a union rate of 95% for unreamed nailing (53% Gustilo type III fractures) and 97% for reamed nailing (43% Gustilo type III fractures); however, bone grafting was required in 15.5% of cases, with up to 32% of cases requiring at least one further procedure to achieve union.⁵ An infection rate of 6% to 7% was reported for IM nailing; stratification by Gustilo types was not reported.

Petrisor et al⁹ reported an infection rate of 62% in open fractures treated with reamed IM nailing. Further analysis revealed that 21% of the infections were idiopathic, with the remaining infections found to be the result of inappropriate soft-tissue closure, compartment syndrome, exchange nailing, or thermal necrosis. A more recent series by Kakar and Tornetta¹⁰ demonstrated the usefulness of immediate nailing of open

Dr. Mehta or an immediate family member is a member of a speakers' bureau or has made paid presentations on behalf of AO and Smith & Nephew and has received nonincome support (such as equipment or services), commercially derived honoraria, or other non-research-related funding (such as paid travel) from Wolters Kluwer Health-Lippincott Williams & Wilkins. None of the following authors or an immediate family member has received anything of value from or owns stock in a commercial company or institution related directly or indirectly to the subject of this article: Dr. Melvin, Dr. Dombroski, Dr. Torbert, Dr. Kovach, and Dr. Esterhai.

tibial shaft fractures. Immediate unreamed IM nailing with meticulous soft-tissue management was found to be safe and effective in 143 open tibial shaft fractures ranging from Gustilo type I through IIIB. A 3% rate of deep infection was reported (1 type I, 2 type II, 1 type IIIB).

Reamed Versus Unreamed Intramedullary Nailing

IM nailing is an effective treatment modality. However, the decision to ream the canal prior to nail insertion is controversial. Insertion of an IM nail after reaming allows for placement of a larger-diameter nail, which may lead to better fracture stability and reduced rates of hardware failure. Reaming is believed to deposit bone graft at the site of fracture. However, it has also been argued that reaming may lead to increased rates of infection and nonunion when it is done in open tibial fractures in which the periosteal blood supply may already be damaged by soft-tissue stripping incurred at the time of injury. Many animal studies have supported this theory by demonstrating that reamed nailing damages the endosteal blood supply to a greater extent than does unreamed nailing.¹¹⁻¹³ In a canine study, reaming of the tibia resulted in damage to 70% of the cortical blood supply, compared with only 31% for unreamed nailing.¹¹ However, Schemitsch and colleagues¹²⁻¹⁴ performed a series of experiments using a sheep tibia model and found that although cortical vascularity reconstituted more slowly with reamed nailing, the amount of new bone formed and the strength of the callus were no different between reamed and unreamed nailing. Thermal necrosis is an additional concern with canal reaming.⁷ The use of sharp reamers, increasing in size by 0.5-mm increments with steady advancement, minimizes heat

generation during reaming and reduces the risk of thermal necrosis.⁷

Clinical studies have not found significantly increased infection or nonunion rates with reaming. A meta-analysis by Bhandari et al¹⁵ failed to demonstrate an increased risk of reoperation (relative risk [RR] = 0.75, 95% confidence interval [CI] = 0.43 to 1.32), nonunion (RR = 0.70, 95% CI = 0.24 to 1.67), or deep infection (RR = 1.02, 95% CI = 0.22 to 4.67) for reamed compared with unreamed nailing in the management of open tibial shaft fractures. Data were recently published by investigators for the Study to Prospectively Evaluate Reamed Intramedullary Nails in Patients with Tibial fractures (SPRINT) trial.¹⁶ This multicenter, blinded, prospective study enrolled 406 open fractures (108 Gustilo type I, 161 type II, 107 type IIIA, 30 type IIIB) and randomized 210 to reamed IM nailing and 196 to unreamed IM nailing. A primary event, defined as revision and/or autodynamization within 1 year, occurred in 29% of reamed tibias and 24% of unreamed tibias. However, this trend toward an increase in primary events in those patients undergoing reamed nailing for open tibia fractures (RR = 1.27, 95% CI = 0.91 to 1.78; *P* = 0.16) did not reach significance. It was concluded that the optimal nailing technique for open fractures remains uncertain. The current clinical evidence does not support the superiority of reamed or unreamed nailing in the treatment open tibial shaft fractures.

External Fixation Versus Intramedullary Nailing

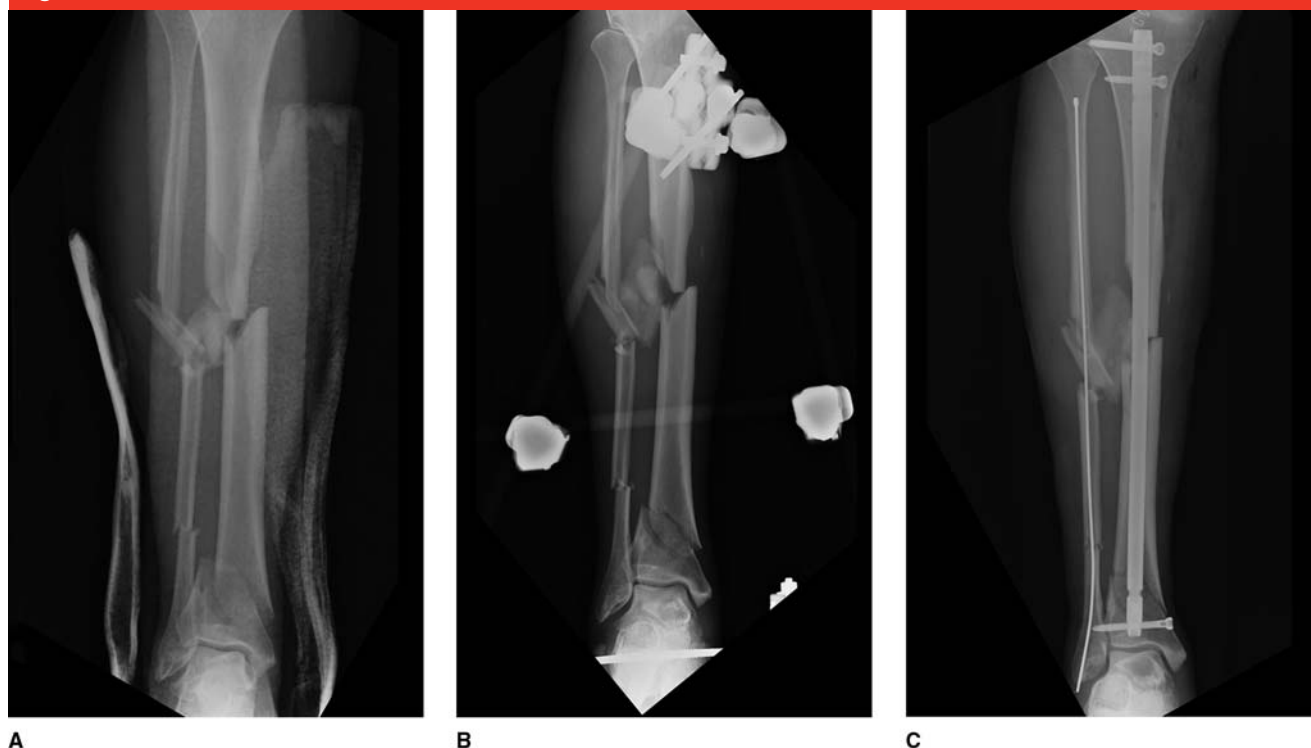Despite the extensive utilization of both external fixation and IM nailing in the treatment of open fractures of the tibial shaft, there is a relative paucity of high-quality studies comparing the efficacy of these treatment methods. A recent meta-analysis of five randomized trials found that unreamed IM nailing

resulted in an 18% reduced risk difference for secondary surgery and a 31% reduced risk difference in the incidence of superficial infection compared with external fixation.¹⁵ IM nailing did not alter the relative risk of nonunion or deep infection in type IIIB open tibia fractures compared with external fixation. No studies included in the meta-analysis directly compared reamed IM nailing with external fixation, so Bhandari et al¹⁵ took an indirect approach, using studies comparing unreamed nails with external fixators and studies comparing reamed and unreamed nails. They found a significantly reduced risk of secondary surgery with reamed nailing (RR = 0.43) compared with external fixation. A more recent meta-analysis also found increased rates of malunion and reoperation for external fixation compared with unreamed IM nailing but demonstrated no difference in the rate of union or deep infection.⁵ Although it appears that IM nailing does not lead to improved healing or infection rates, it is often preferable to external fixation because it offers superior maintenance of alignment, a lower secondary surgery rate, and better tolerance by the patients and nurses.

Secondary Intramedullary Nailing Following External Fixation

Although IM nailing is the preferred treatment of most open tibial shaft fractures, external fixation is still commonly used for temporary stabilization in cases of massive soft-tissue damage or as part of a damage-control protocol (Figure 1). Early studies demonstrated high rates of infection after conversion to IM nailing.^{17,18} More recent studies, including a prospective randomized trial, have demonstrated deep infection rates of approximately 5% to 6%.^{8,19} These studies typically em-

Figure 1



A, AP radiograph demonstrating open segmental tibial shaft fracture in a patient with bilateral lung injury, cervical spine injury, and a forearm fracture involving both bones. **B**, AP radiograph showing fracture stabilization with external fixation as part of a damage-control protocol. **C**, AP radiograph obtained after conversion from external fixation to an intramedullary nail with fixation of the fibula to provide added stability to the lateral soft tissue.

ployed a “safety interval” of casting or bracing between removal of the external fixator and IM nailing to allow granulation of pin sites. A recent meta-analysis of level III and IV studies identified nine studies (268 patients, 212 open fractures) that reported on planned conversion from external fixation to IM nailing for tibial shaft fractures.²⁰ Infection was reported in 9% of patients, and union was reported in 90% of fractures. Shorter duration of external fixation (≤ 28 days) resulted in a significantly reduced rate of infection than with longer external fixation (>28 days) (3.7% versus 22%, respectively). However, contrary to previous reports, an interval of <14 days between removal of the external fixator and IM nailing was associated with a significant reduction in

infection rate ($P < 0.001$). Recently, successful conversion from external fixation to IM nailing in type IIIB open tibia fractures without a safety interval was reported.²¹

We advocate conversion to IM nailing as soon as the patient is able to tolerate the procedure and adequate soft-tissue coverage is attained. A safety interval of <10 days should be used in the management of pin-tract infections, with débridement, irrigation, and antibiotics, to allow for pin-tract granulation before IM nailing.

Orthobiologics, Ultrasound, and Electrical Stimulation

The high-energy nature of open tibial diaphyseal fractures, the extensive

soft-tissue injury and devitalization of bone involved, and the increased risk of infection predispose these fractures to impaired healing. The four components required for fracture healing are adequate blood supply, the presence of connective-tissue progenitor cells, a stable osteoconductive scaffold, and growth factors and cytokines. Improved understanding of each of these aspects of fracture healing has led to the development of orthobiologics. Many of these novel therapeutic interventions are amenable for use in open tibia fracture.

The most extensively studied orthobiologics in open tibia fractures are bone morphogenetic proteins (BMPs). These members of the transforming growth factor- β superfamily play a vital role in fracture healing by

inducing mesenchymal stem cells (MSCs) to differentiate into osteogenic progenitor cells. BMP-2 (Infuse; Medtronic Sofamor Danek, Memphis, TN) and BMP-7 (OP-1; Stryker, Mahwah, NJ) have been evaluated in randomized clinical trials for their clinical efficacy in the management of open tibia fractures.

In a multicenter prospective, randomized clinical trial, the BMP-2 Evaluation in Surgery for Tibial Trauma (BESTT) study group reported the results of BMP-2 in the management of open tibia fractures.²² The control group received the standard of care (ie, routine soft-tissue management and IM nailing), and the treatment group received that standard of care plus BMP-2 on a collagen carrier implanted at the fracture site at the time of wound closure. Two different doses were used in this study (0.75 and 1.5 mg/mL). Although a dose-response was observed, the significant effects of BMP-2 on fracture union occurred at the higher dose (1.5 mg/mL). Compared with controls, the patients treated with 1.5 mg/mL BMP-2 had a significantly reduced number of secondary interventions (44% risk reduction; $P = 0.0005$) and accelerated fracture healing (average of 39 days faster). Fewer infections were found in Gustilo type IIIA and IIIB fractures treated with BMP-2. Subsequent subgroup analysis of type IIIA and IIIB open tibia fractures incorporating an additional 39 patients from a similar unpublished US study confirmed a significant reduction in secondary interventions when these open fractures were treated with 1.5 mg/mL recombinant human BMP-2 (rhBMP-2) ($P = 0.02$).²³

BMP-7 was investigated in a prospective, randomized trial by the Canadian Orthopaedic Trauma Society.²⁴ This group demonstrated a reduction in secondary procedures when BMP-7 was used in conjunc-

tion with standard wound treatment and fracture fixation of open tibia fractures. BMP-7 also had a positive effect on fracture union and overall function.

Currently, only BMP-2 is FDA-approved for use in acute open tibia fractures that have been stabilized with IM nailing after appropriate wound management in skeletally mature individuals. A European cost analysis of the use of BMP-2 for open tibia fractures predicted the routine use of BMP-2 to be more cost-effective than fracture fixation alone based on the anticipated reduction in delayed union and secondary procedures.²⁵ Despite the predicted savings, many insurance plans do not reimburse for the use of BMP-2 in acute open tibia fractures.

MSCs are crucial to fracture healing. These osteogenic cells have been isolated and incorporated in many animal studies to enhance fracture healing, but no similar reports have been described in human studies of open tibia fractures.²⁶ However, a recent series by Hammer et al²⁷ demonstrated healing of large segmental tibial and femoral bone defects in sheep with the use of the Reamer/Irrigator/Aspirator (Synthes USA, West Chester, PA) to harvest filtered autologous cancellous bone graft from intramedullary reamings. Although this technique did not isolate MSCs, other studies have shown that collected intramedullary reamings do contain a combination of connective tissue progenitor cells and growth factors.^{28,29} Further research is warranted to determine the true osteogenic potential of these reamings and their effect on fracture healing.

Physical forces such as ultrasound and electrical stimulation have also been investigated for their role in fracture healing. The use of these modalities has generally focused on the treatment of nonunions; however, low-intensity ultrasound has

been shown to augment fracture healing in fresh fractures, as well.³⁰ The mechanism by which ultrasound stimulates fracture healing is unclear, but it has been shown to modulate gene expression and ion flux in bone and cartilage cells in multiple phases of healing.³¹ In a prospective, randomized, double-blind trial, Heckman et al³⁰ demonstrated earlier fracture healing in closed and type I open tibia fractures managed with cast immobilization and low-intensity ultrasound. Further analysis of these data revealed a 41% decrease in healing time in patients who smoked.³² Conversely, Emami et al³³ found no difference between ultrasound and placebo in tibia fractures managed with IM nailing. The use of IM nailing and a shorter duration of ultrasound may account for the discrepancy in outcomes in this study. Nevertheless, low-intensity ultrasound remains a valuable adjunct in the management of tibia fractures, especially in patients at greater risk of nonunion (ie, because of smoking, obesity, open fracture).

Similar to the use of low-intensity ultrasound, the role of electrical stimulation in fracture healing has focused on delayed union and nonunion. In vitro studies clearly show molecular changes in response to such treatment.^{34,35} However, no study has evaluated the effect of this treatment in acute open tibia fractures.

Limb Salvage and Amputation

Type III open tibia fractures, particularly type IIIB and IIIC injuries, may be associated with such tremendous damage to the bone and surrounding soft-tissue structures that primary or early amputation must be weighed against limb salvage. The decision to amputate or reconstruct the injured

limb is complex and involves the consideration of several variables. When possible, the difficult decision to pursue limb salvage or to amputate must be made in open collaboration with the wishes and goals of the patient, family, and physician. When amputation is deemed appropriate in the acute or subacute setting, a second opinion should be documented in the medical record from another orthopaedic surgeon or, preferably, a surgeon from another discipline (eg, vascular, trauma, plastic). Photographs taken at the time of injury and initial débridement as well as documentation of family discussions often prove to be beneficial.

Numerous objective scoring systems have been proposed to aid in the identification of injuries suitable for limb salvage, such as the mangled extremity severity score; the predictive salvage index; the limb salvage index; and the nerve injury, ischemia, soft tissue, skeletal injury, shock and age of patient score. However, a retrospective study by Bonanni et al³⁶ found that these scoring systems could not predict successful limb salvage. This was supported by a prospective evaluation done by the Lower Extremity Assessment Project (LEAP) study group, which found that scores at or above the amputation threshold did not correlate with actual limb salvage rates.³⁷

The financial impact of limb salvage versus amputation was recently analyzed by MacKenzie et al.³⁸ The authors analyzed the cost of hospitalizations, secondary surgery, rehabilitation, and prostheses. Amputation was found to be more costly than limb salvage, with most of the added expense attributed to purchase of a prosthesis and to lifetime maintenance. When prosthesis costs were ignored, there was no difference between amputation and limb salvage. The authors concluded that

limb salvage should be pursued when possible.

Recently, the LEAP study group followed 569 patients to investigate the outcome of limb salvage versus reconstruction for severe lower extremity trauma and to elucidate the variables important for predicting outcome.³⁹ At 7 years postinjury, patients who underwent limb salvage and primary amputees were found to have similarly poor outcomes.⁴⁰ Perhaps more importantly, the LEAP series demonstrated that overall functional outcomes were affected more by a patient's economic, social, and personal resources than by the treatment course or by more traditional variables such as fracture healing and joint function. Variables associated with a poor prognosis include smoking, nonwhite race, poverty, lack of private health insurance, poor social support, and involvement in disability litigation. Self-efficacy—the confidence to be able to perform specific tasks—was associated with improved outcome and return to work⁴¹ (Table 1). Although several of these variables are difficult to change, assisting the patient early in the course of recovery with psychosocial interventions such as self-management programs, counseling, and vocational rehabilitation may lead to improved overall function.

Soft-tissue Reconstruction

Because of the extensive soft-tissue damage involved, type IIIB and IIIC tibia fractures often require soft-tissue reconstruction for wound coverage. Reconstruction of the soft-tissue envelope with durable vascularized coverage is vitally important for fracture recovery. The improved vascularity to the wound bed afforded by reconstruction decreases infection rates by improving delivery of antibiotics, promoting native im-

Table 1

Predictors of a Poor Sickness Impact Profile Score at 2 and 7 Years Following Lower Extremity Injury

2-year Patient Predictors

- Rehospitalization for a major complication
- Low education level
- Nonwhite race
- Poverty
- Lack of private health insurance
- Poor social support network
- Low self-efficacy
- Smoking
- Involvement in disability compensation litigation

7-year Patient Predictors

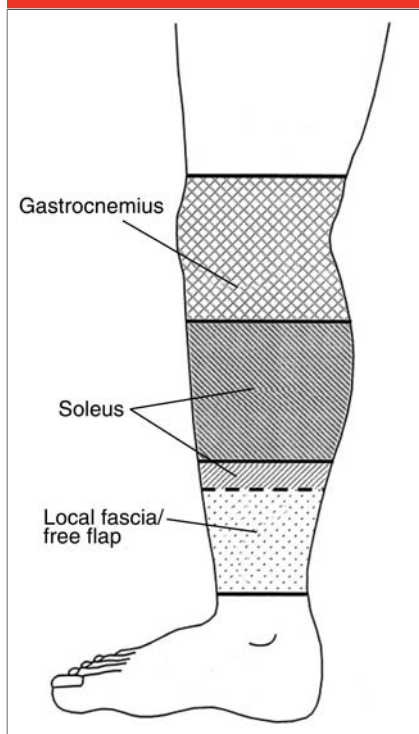
- Older age
- Female sex
- Nonwhite race
- Lower education level
- Living in a poor household
- Current or previous smoking
- Low self-efficacy
- Poor self-reported health status before injury
- Involvement in disability compensation litigation

Adapted with permission from Cannada LK, Jones AL: Demographic, social and economic variables that affect lower extremity injury outcomes. *Injury* 2006;37:1109-1116. <http://www.sciencedirect.com/00201383>.

mune responses, and covering the wound from the environment, thereby reducing the risk of nosocomial infection. Additionally, soft-tissue reconstruction promotes fracture and soft-tissue healing and prevents wound desiccation.

Reconstruction of the soft tissues about the tibia is typically achieved through the use of local rotational flaps, fasciocutaneous flaps, or free-tissue transfer (Figure 2). The location, size, and volume of the defect, as well as the extent of local soft-tissue damage, often determine the reconstruction method. Local rotational flaps may be used in the upper

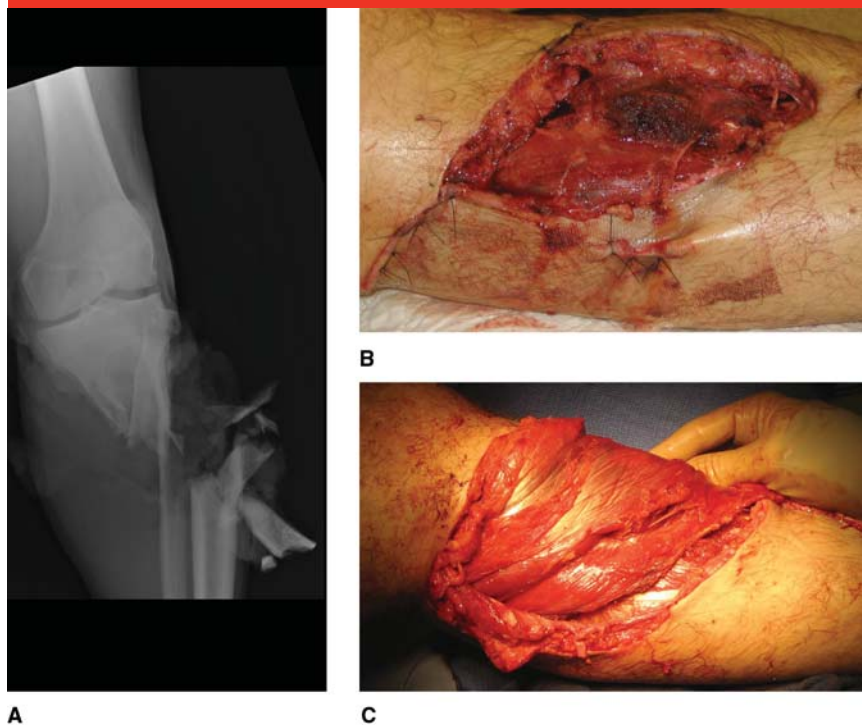
Figure 2



Schematic representation of the soft-tissue coverage options for vascularized flap selection by anatomic wound location in the management of open tibial shaft fractures. (Adapted with permission from Hallock GG: Utility of both muscle and fascia flaps in severe lower extremity trauma. *J Trauma* 2000;48:913-917.)

two thirds of the tibia. Typically, a gastrocnemius flap may be rotated into a defect in the superior third of the tibia, whereas a soleus flap can be used for coverage in the middle third of the tibia (Figure 3). However, these flaps typically reside in the zone of injury, and the surgeon must consider the extent of damage to the muscle to be transferred when determining treatment. Pollak et al⁴² found a higher wound complication rate for rotational flaps compared with free flaps for AO/OTA type C fractures (44% versus 23%, respectively). The higher complication rate for higher-energy fractures highlights the importance of taking into ac-

Figure 3



A, AP radiograph of a comminuted open fracture at the metaphyseal-diaphyseal junction. **B**, Clinical photograph of the corresponding soft-tissue defect after thorough débridement and irrigation. **C**, Clinical photograph of the soft-tissue defect following coverage with a rotational gastrocnemius flap but before skin grafting. The gastrocnemius muscle was viable in this patient. Given the proximal-medial location of the wound, the rotational flap adequately covered the defect. A free flap would have been a reasonable alternative for this injury.

count the extent of local tissue trauma when considering a rotational flap.

Fasciocutaneous flaps are composites of skin, subcutaneous tissue, and fascia that obtain their blood supply from one or multiple fasciocutaneous perforators. When used as a rotational flap, they are typically random pattern flaps without an axial blood supply. However, local tissue trauma, especially shearing injury, which could tear fasciocutaneous perforators, is a relative contraindication to local fasciocutaneous flaps because the trauma may render these flaps unreliable secondary to a compromised blood supply. Nevertheless, fasciocutaneous flaps are less bulky,

may be raised locally or free, and are useful when dead space is minimal, which may be the case in open distal third tibia fractures. Cole et al⁴³ successfully used local fasciocutaneous flaps for early coverage of 50 consecutive open tibia fractures of all types and locations followed for 21 months, reporting a 98% union rate and a 2% infection rate. In four patients, gradual limb shortening was done to achieve fasciocutaneous flap coverage before performing tibial lengthening over an IM nail. In a recent retrospective study, Yazar et al⁴⁴ found similar outcomes between fasciocutaneous flaps and free muscle flaps for treatment of open distal third tibia fractures.

Free-tissue transfer (ie, free flaps) can provide large volumes of undamaged, well-vascularized tissue to cover large defects or three-dimensional wounds with dead space. This technique has been shown to improve tissue oxygenation and decrease the risk of infection. Free muscle flaps covered by a split-thickness skin graft are typically used for open fractures with significant tissue loss. However, free fasciocutaneous flaps have also been successfully used in these cases. Recent evidence suggests that outcomes are equivalent between free fasciocutaneous and free muscle flaps for open distal tibia and ankle fracture defects.⁴⁴ Thus, choice of flap coverage should depend on the size and three-dimensionality of the defect, available donor vessels, and available donor sites.

Osteocutaneous flaps for segmental defects of the tibia can be used for bony defects of >6 cm in length.^{45,46} Available osteocutaneous flaps include the fibula and the iliac crest; however, the iliac crest is limited to a length of 10 cm. Free osteocutaneous flaps have the advantage of preservation of blood supply and thus provide viable bone without the need for creeping substitution. Free osteocutaneous flaps in the acute setting should be considered for a tibial defect of >6 cm, with or without an associated soft-tissue defect, and when preservation of length is desired. Another option for reconstruction of a bony defect with soft-tissue injury includes acute shortening of the tibia followed by ring fixation and bone transport. Often, a secondary surgery is required to obtain union of the docking site once the soft tissue and bone have been appropriately lengthened.⁴⁷

Timing of Coverage

Soft-tissue reconstruction should be performed within 7 to 10 days after

injury. The literature is inconsistent with regard to the optimal timing of reconstruction, but studies have consistently shown that delays in reconstructive wound coverage are associated with increased infection and flap failure rates.

In one of the first series to report the benefits of early reconstruction, Godina⁴⁸ found that delayed reconstruction of severe open wounds beyond 72 hours resulted in an increase in the postoperative infection rate, from 1.5% to 17.5%, and in the free-flap failure rate, from 0.75% to 12%. Gopal et al⁴⁹ confirmed that aggressive combined orthopaedic and plastic surgical treatment provides good results. Their series reported a deep infection rate of 6% when reconstruction was performed within 72 hours for type IIIB and IIIC tibia fractures (4 of 63 cases). Fischer et al⁵⁰ showed that soft-tissue coverage of type IIIB tibia fractures ≤10 days of injury resulted in a lower infection rate compared with fractures that were covered at >10 days and with wounds that were allowed to granulate (18%, 69%, and 53%, respectively). In a recent series, Tielinen et al⁵¹ found no infections in a consecutive group of 19 patients with type IIIB and IIIC tibia fractures treated with immediate unreamed IM nailing and soft-tissue reconstruction within 48 hours of injury. Although the available evidence highlights the benefits of early soft-tissue reconstruction, these retrospective series may be confounded by delayed treatment of the more severe injuries and by the absence of comparison with other methods of wound coverage.

Summary

The definitive treatment of open tibial shaft fractures remains challenging. These fractures should be

classified at the time of surgical débridement according to the system of Gustilo and Anderson to guide treatment and predict outcome.⁵² Currently, IM fixation is the preferred method of fracture stabilization. External fixation is appropriate in cases of severe contamination and in the setting of damage-control orthopaedics. Conversion to IM nailing should occur within 28 days after injury, with a safety interval employed prior to IM nailing when pin-tract infection is suspected. Prompt, definitive soft-tissue coverage within 7 days decreases the rate of deep infection and should be a priority. Despite improvements in antibiotic prophylaxis, fracture stabilization, orthobiologics, and plastic surgical techniques, injury severity and patient psychosocial factors have the greatest impact on overall functional outcomes as well as infection and union rates.

The first part of this article, "Open Tibial Shaft Fractures: I. Evaluation and Initial Wound Management," was published in the January 2010 issue of the *Journal of the American Academy of Orthopaedic Surgeons*.

References

Evidence-based Medicine: Levels of evidence are described in the table of contents. In this article, references 16, 22, 23, and 35 are level I studies. Level II studies include references 2, 15, 19, 20, 30, 38-40, 42, 49, and 50. References 1, 5, 8, 10, 43, and 48 are level III studies. References 3, 4, 6, 9, 17, 18, 21, 44-48, and 49 are level IV studies.

Citation numbers printed in **bold type** indicate references published within the past 5 years.

1. Puno RM, Teynor JT, Nagano J, Gustilo RB: Critical analysis of results of treatment of 201 tibial shaft fractures. *Clin Orthop Relat Res* 1986;212:113-121.
2. Bach AW, Hansen ST Jr: Plates versus external fixation in severe open tibial shaft fractures: A randomized trial. *Clin Orthop Relat Res* 1989;241:89-94.
3. Clifford RP, Beauchamp CG, Kellam JF, Webb JK, Tile M: Plate fixation of open fractures of the tibia. *J Bone Joint Surg Br* 1988;70:644-648.
4. Dunbar RP, Nork SE, Barei DP, Mills WJ: Provisional plating of type III open tibia fractures prior to intramedullary nailing. *J Orthop Trauma* 2005;19:412-414.
5. Giannoudis PV, Papakostidis C, Roberts C: A review of the management of open fractures of the tibia and femur. *J Bone Joint Surg Br* 2006;88:281-289.
6. Sen C, Kocaoglu M, Eralp L, Gulsen M, Cinar M: Bifocal compression-distraction in the acute treatment of grade III open tibia fractures with bone and soft-tissue loss: A report of 24 cases. *J Orthop Trauma* 2004;18:150-157.
7. French B, Tornetta P III: High-energy tibial shaft fractures. *Orthop Clin North Am* 2002;33:211-230.
8. Blachut PA, Meek RN, O'Brien PJ: External fixation and delayed intramedullary nailing of open fractures of the tibial shaft: A sequential protocol. *J Bone Joint Surg Am* 1990;72:729-735.
9. Petrisor B, Anderson S, Court-Brown CM: Infection after reamed intramedullary nailing of the tibia: A case series review. *J Orthop Trauma* 2005;19:437-441.
10. Kakar S, Tornetta P III: Open fractures of the tibia treated by immediate intramedullary tibial nail insertion without reaming: A prospective study. *J Orthop Trauma* 2007;21:153-157.
11. Klein MP, Rahn BA, Frigg R, Kessler S, Perren SM: Reaming versus non-reaming in medullary nailing: Interference with cortical circulation of the canine tibia. *Arch Orthop Trauma Surg* 1990;109:314-316.
12. Schemitsch EH, Kowalski MJ, Swiontkowski MF, Senft D: Cortical bone blood flow in reamed and unreamed locked intramedullary nailing: A fractured tibia model in sheep. *J Orthop Trauma* 1994;8:373-382.
13. Schemitsch EH, Kowalski MJ, Swiontkowski MF, Harrington RM: Comparison of the effect of reamed and unreamed locked intramedullary nailing on blood flow in the callus and strength of union following fracture of the sheep tibia. *J Orthop Res* 1995;13:382-389.
14. Schemitsch EH, Turchin DC, Kowalski MJ, Swiontkowski MF: Quantitative assessment of bone injury and repair after reamed and unreamed locked intramedullary nailing. *J Trauma* 1998;45:250-255.
15. Bhandari M, Guyatt GH, Swiontkowski MF, Schemitsch EH: Treatment of open fractures of the shaft of the tibia. *J Bone Joint Surg Br* 2001;83:62-68.
16. Study to Prospectively Evaluate Reamed Intramedullary Nails in Patients with Tibial Fractures Investigators, Bhandari M, Guyatt G, et al: Randomized trial of reamed and unreamed intramedullary nailing of tibial shaft fractures. *J Bone Joint Surg Am* 2008;90:2567-2578.
17. Maurer DJ, Merkow RL, Gustilo RB: Infection after intramedullary nailing of severe open tibial fractures initially treated with external fixation. *J Bone Joint Surg Am* 1989;71:835-838.
18. McGraw JM, Lim EV: Treatment of open tibial-shaft fractures: External fixation and secondary intramedullary nailing. *J Bone Joint Surg Am* 1988;70:900-911.
19. Antich-Adrover P, Martí-Garin D, Murias-Alvarez J, Puente-Alonso C: External fixation and secondary intramedullary nailing of open tibial fractures: A randomised, prospective trial. *J Bone Joint Surg Br* 1997;79:433-437.
20. Bhandari M, Zlowodzki M, Tornetta P III, Schmidt A, Templeman DC: Intramedullary nailing following external fixation in femoral and tibial shaft fractures. *J Orthop Trauma* 2005;19:140-144.
21. Ueno M, Yokoyama K, Nakamura K, Uchino M, Suzuki T, Itoman M: Early unreamed intramedullary nailing without a safety interval and simultaneous flap coverage following external fixation in type IIIB open tibial fractures: A report of four successful cases. *Injury* 2006;37:289-294.
22. Govender S, Csimma C, Genant HK, et al: Recombinant human bone morphogenetic protein-2 for treatment of open tibial fractures: A prospective, controlled, randomized study of four hundred and fifty patients. *J Bone Joint Surg Am* 2002;84:2123-2134.
23. Swiontkowski MF, Aro HT, Donell S, et al: Recombinant human bone morphogenetic protein-2 in open tibial fractures: A subgroup analysis of data combined from two prospective randomized studies. *J Bone Joint Surg Am* 2006;88:1258-1265.
24. McKee MD, Schemitsch EH, Waddell JP, et al: Abstract: The effect of human recombinant bone morphogenetic protein (RHBMP-7) on the healing of open tibial shaft fractures: Results of a multi-center, prospective, randomized clinical trial. *Final Program of the 18th Annual Meeting of the Orthopaedic Trauma Association*. Rosemont, IL, Orthopaedic Trauma Association, 2002, paper #45. Available at: <http://www.hwbf.org/ota/am/ota02/otapa/OTA02745.htm>. Accessed October 15, 2009.
25. Alt V, Heissel A: Economic considerations for the use of recombinant human bone morphogenetic protein-2 in open tibial fractures in Europe: The German model. *Curr Med Res Opin* 2006;22(suppl 1):S19-S22.
26. Bielby R, Jones E, McGonagle D: The role of mesenchymal stem cells in maintenance and repair of bone. *Injury* 2007;38(suppl 1):S26-S32.
27. Hammer TO, Wieling R, Green JM, Südkamp NP, Schneider E, Müller CA: Effect of re-implanted particles from intramedullary reaming on mechanical properties and callus formation: A laboratory study. *J Bone Joint Surg Br* 2007;89:1534-1538.
28. Schmidmaier G, Herrmann S, Green J, et al: Quantitative assessment of growth factors in reaming aspirate, iliac crest, and platelet preparation. *Bone* 2006;39:1156-1163.
29. Wenisch S, Trinkaus K, Hild A, et al: Human reaming debris: A source of multipotent stem cells. *Bone* 2005;36:74-83.
30. Heckman JD, Ryaby JP, McCabe J, Frey JJ, Kilcoyne RF: Acceleration of tibial fracture-healing by non-invasive, low-intensity pulsed ultrasound. *J Bone Joint Surg Am* 1994;76:26-34.
31. Khan Y, Laurencin CT: Fracture repair with ultrasound: Clinical and cell-based evaluation. *J Bone Joint Surg Am* 2008;90(suppl 1):S138-S144.
32. Cook SD, Ryaby JP, McCabe J, Frey JJ, Heckman JD, Kristiansen TK: Acceleration of tibia and distal radius fracture healing in patients who smoke. *Clin Orthop Relat Res* 1997;337:198-207.
33. Emami A, Petrén-Mallmin M, Larsson S: No effect of low-intensity ultrasound on healing time of intramedullary fixed tibial fractures. *J Orthop Trauma* 1999;13:252-257.
34. Wang Z, Clark CC, Brighton CT: Up-regulation of bone morphogenetic proteins in cultured murine bone cells with use of specific electric fields. *J Bone Joint Surg Am* 2006;88:1053-1065.
35. Brighton CT, Fisher JR Jr, Levine SE, et al: The biochemical pathway mediating the proliferative response of bone cells to a mechanical stimulus. *J Bone Joint Surg Am* 1996;78:1337-1347.

36. Bonanni F, Rhodes M, Lucke JF: The futility of predictive scoring of mangled lower extremities. *J Trauma* 1993;34:99-104.
37. Bosse MJ, MacKenzie EJ, Kellam JF, et al: A prospective evaluation of the clinical utility of the lower-extremity injury-severity scores. *J Bone Joint Surg Am* 2001;83:3-14.
38. MacKenzie EJ, Jones AS, Bosse MJ, et al: Health-care costs associated with amputation or reconstruction of a limb-threatening injury. *J Bone Joint Surg Am* 2007;89:1685-1692.
39. Bosse MJ, MacKenzie EJ, Kellam JF, et al: An analysis of outcomes of reconstruction or amputation after leg-threatening injuries. *N Engl J Med* 2002;347:1924-1931.
40. MacKenzie EJ, Bosse MJ, Pollak AN, et al: Long-term persistence of disability following severe lower-limb trauma: Results of a seven-year follow-up. *J Bone Joint Surg Am* 2005;87:1801-1809.
41. Cannada LK, Jones AL: Demographic, social and economic variables that affect lower extremity injury outcomes. *Injury* 2006;37:1109-1116.
42. Pollak AN, McCarthy ML, Burgess AR: Short-term wound complications after application of flaps for coverage of traumatic soft-tissue defects about the tibia: The Lower Extremity Assessment Project (LEAP) Study Group. *J Bone Joint Surg Am* 2000;82:1681-1691.
43. Cole JD, Ansel LJ, Schwartzberg R: A sequential protocol for management of severe open tibial fractures. *Clin Orthop Relat Res* 1995;315:84-103.
44. Yazar S, Lin CH, Lin YT, Ulusal AE, Wei FC: Outcome comparison between free muscle and free fasciocutaneous flaps for reconstruction of distal third and ankle traumatic open tibial fractures. *Plast Reconstr Surg* 2006;117:2468-2475.
45. Osterman AL, Bora FW: Free vascularized bone grafting for large-gap nonunion of long bones. *Orthop Clin North Am* 1984;15:131-142.
46. Weiland AJ, Moore JR, Daniel RK: Vascularized bone autografts: Experience with 41 cases. *Clin Orthop Relat Res* 1983;174:87-95.
47. Mekhail AO, Abraham E, Gruber B, Gonzalez M: Bone transport in the management of posttraumatic bone defects in the lower extremity. *J Trauma* 2004;56:368-378.
48. Godina M: Early microsurgical reconstruction of complex trauma of the extremities. *Plast Reconstr Surg* 1986;78:285-292.
49. Gopal S, Majumder S, Batchelor AG, Knight SL, De Boer P, Smith RM: Fix and flap: The radical orthopaedic and plastic treatment of severe open fractures of the tibia. *J Bone Joint Surg Br* 2000;82:959-966.
50. Fischer MD, Gustilo RB, Varecka TF: The timing of flap coverage, bone-grafting, and intramedullary nailing in patients who have a fracture of the tibial shaft with extensive soft-tissue injury. *J Bone Joint Surg Am* 1991;73:1316-1322.
51. Tielinen L, Lindahl JE, Tukiainen EJ: Acute unreamed intramedullary nailing and soft tissue reconstruction with muscle flaps for the treatment of severe open tibial shaft fractures. *Injury* 2007;38:906-912.
52. Gustilo RB, Anderson JT: Prevention of infection in the treatment of one thousand and twenty-five open fractures of long bones: Retrospective and prospective analyses. *J Bone Joint Surg Am* 1976;58:453-458.