

## Technical Note

# Arthroscopic Fixation of Bursal-Sided Rotator Cuff Tears

Andrew B. Wolff, David P. Magit, Seth R. Miller, Jeff Wyman, and Paul M. Sethi

---

**Abstract:** Subacromial decompression and debridement of partial-thickness bursal-sided rotator cuff tears are often reported with a high rate of unsatisfactory outcomes. We describe an arthroscopic procedure to repair partial-thickness bursal-sided rotator cuff tears without converting to a full-thickness tear in patients with a normal articular-sided rotator cuff and an A0B2 or A0B3 pattern of tear (minimum thickness of 25% to 75%). The articular side of the rotator cuff experiences greater tension than the bursal side of the cuff. As such, by leaving the articular footprint intact, we accomplish 3 goals: the intact articular fibers act as an internal splint to protect the bursal-sided repair, a wide and anatomic footprint is recreated, and we are able to minimize any length-tension mismatch because the tissue is not excessively lateralized with repair. After bursectomy and acromioplasty, the frayed edges of the bursal flap are gently debrided and the tuberosity is excoriated to bleeding bone. One or two bioabsorbable anchors are placed, and both sutures are placed through the full thickness of the rotator cuff (one anterior and one posterior) by use of a percutaneous suture lasso in this manner: (1) the lasso is passed through the full thickness of the cuff, and the nitinol wire is shuttled out of a single cannula along with the more medial of the suture limbs; (2) the nitinol wire is then pulled back out of the percutaneous portal along with the suture limb, with the suture being passed through the full thickness of the cuff; and (3) the procedure is repeated for the posterior limb of the suture after a lasso is again passed through the full thickness of the rotator cuff in a more posterior position. This subset of patients is treated with an aggressive rehabilitation protocol because the intact articular rotator cuff fibers act as an internal splint to protect the bursal repair. **Key Words:** Rotator cuff—Arthroscopy—Partial-thickness rotator cuff tear.

---

**A**dvances in shoulder arthroscopy and magnetic resonance imaging continue to increase the understanding and treatment of rotator cuff disease, par-

---

*From the Department of Orthopaedics and Rehabilitation, Yale University School of Medicine (A.B.W., D.P.M.), New Haven, Connecticut; Orthopedic Sports Medicine, Orthopedic and Neurosurgical Specialists (S.R.M., P.M.S.), Greenwich, Connecticut; and Arthrex (J.W.), Naples, Florida, U.S.A.*

*J. W. is an employee of Arthrex, Naples, Florida. The authors report no other conflicts of interest.*

*Address correspondence and reprint requests to Paul M. Sethi, M.D., Orthopedic Sports Medicine, Orthopedic and Neurosurgical Specialists, 6 Greenwich Office Park, Greenwich, CT 06839, U.S.A. E-mail: sethi@onsmd.com*

© 2006 by the Arthroscopy Association of North America

*Cite this article as: Wolff AB, Magit DP, Miller SR, Wyman J, Sethi PM. Arthroscopic fixation of bursal-sided rotator cuff tears. Arthroscopy 2006;22:1247.e1-1247.e4 [doi:10.1016/j.arthro.2006.05.026].*

0749-8063/06/2211-5111\$32.00/0

doi:10.1016/j.arthro.2006.05.026

ticularly partial-thickness tears. The treatment for partial-thickness rotator cuff tears, both articular- and bursal-sided, has been uniform despite the significant evidence that there are differences in the pathology, cause, prognosis, and preferred treatment. Cordasco et al.<sup>1</sup> reported their results of patients with grade 0, 1A, 2A, 1B, or 2B partial rotator cuff tears treated with arthroscopic acromioplasty and debridement of the cuff tear with a mean follow-up of 4.5 years. They found a significantly higher failure rate in grade 2B patients versus grade 2A patients (38% v 5%), as well as a significantly higher overall failure rate for patients with bursal-sided tears (grades 1B and 2B) than for patients with articular-sided tears (grades 1A and 2A) (29% v 3%).

Because of these findings, which suggest that treatment of partial-thickness bursal-sided rotator cuff tears (PTBRCTs) via arthroscopic acromioplasty and debridement alone is not adequate, we describe an

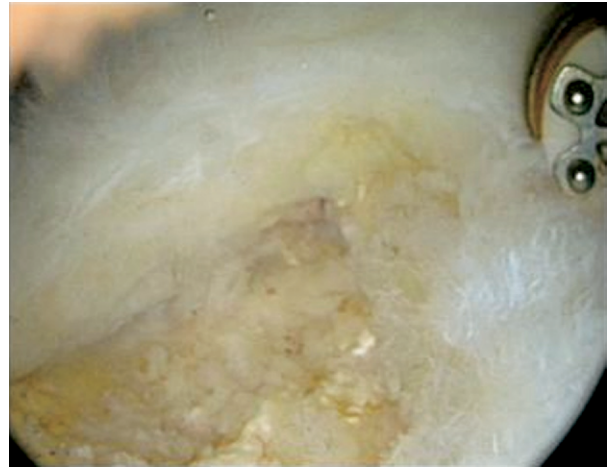
arthroscopic procedure to repair these tears and report our preliminary results.

### SURGICAL TECHNIQUE

Diagnostic arthroscopy through a standard posterior portal is carried out in all patients. All intra-articular structures are carefully probed with an instrument inserted through the rotator interval. Attention is then turned to the subacromial space. An atraumatic bursectomy is routinely performed through the midlateral portal to assess the status of the coracoacromial ligament and bursa. Subsequently, a complete bursectomy is carried out with a motorized shaver and arthroscopic electrocautery. The coracoacromial ligament is inspected for fraying. The cuff is then inspected from both the posterior-lateral and midlateral lateral portals and carefully probed.

When present, the PTBRCT is graded according to the classification system described by Ellman.<sup>2</sup> This system differentiates partial-thickness tears based on location (articular [A], bursal [B], or interstitial [C]) and thickness of the tear, with grade 1 being less than 3 mm deep, grade 2 being 3 to 6 mm deep, and grade 3 being more than 6 mm deep but not full thickness.<sup>2</sup> Patients with an A0B2 or A0B3 pattern of tear within the supraspinatus tendon that correlates with magnetic resonance imaging findings are candidates for this procedure. Patients with near full-thickness tears (>75%) are not included, because these tears are completed and repaired with a double-row arthroscopic repair.

The frayed edges of the bursal-sided flap are identified and gently debrided with an arthroscopic biter and oscillating shaver until normal cuff attachment is visualized anteriorly and posteriorly (Fig 1). Careful attention is given not to take down the intact articular fibers of the cuff insertion; the motorized shaver tends to debride incompetent tissue and leave behind intact fibers. If the tear enlarges well beyond 75% of the footprint, the residual fibers are taken down and repaired in a double-row fashion; this happens infrequently. The greater tuberosity is excoriated, not decorticated, to bleeding bone with a round burr. One or two bioabsorbable suture anchors that are double loaded with No. 2 FiberWire (Arthrex, Naples, FL) are placed through a percutaneous stab wound just off of the lateral edge of the acromion; the position and angle of approach are predetermined by use of a spinal needle. After the anchor is placed, one limb from each of the sutures is placed through the full thickness of the rotator cuff (one limb in the anterior cuff and one

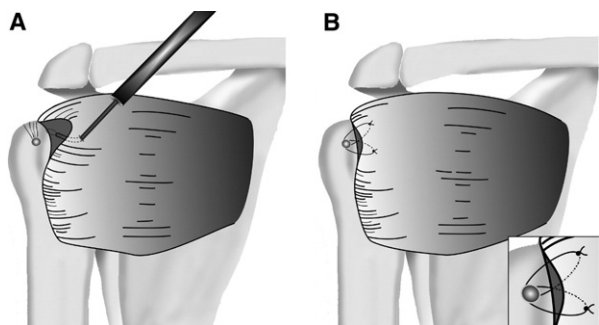


**FIGURE 1.** Bursal-sided partial-thickness tear after debridement showing intact anterior and posterior attachments of rotator cuff as visualized through midlateral portal.

in the posterior) by use of a percutaneous suture lasso in the following manner: (1) the suture lasso is passed through the full thickness of the cuff through a percutaneous portal, which optimizes the angle required for repair (often accomplished through the Neviaser portal, the superior-medial portal bordered by the clavicle, the acromioclavicular joint, and the spine of the scapula), and the nitinol wire is shuttled out of a cannula along with the more medial of the suture limbs; (2) the nitinol wire is then pulled back out of the percutaneous portal along with the suture limb, with the suture being passed through the full thickness of the cuff; and (3) the procedure is repeated for the posterior limb of the suture after a lasso is again passed through the full thickness of the rotator cuff in a more posterior position (Fig 2A). If the tear is greater than 1.5 cm in anterior-to-posterior dimensions, then 2 suture anchors are placed and the procedure is repeated.

After both sutures are passed through the cuff, the anterior set of sutures is shuttled out through the single cannula (usually midlateral) and tied, followed by the posterior set of sutures. Both sutures are tied securely on the bursal surface of the cuff by use of a sliding knot with 3 alternating half hitches, which include alternating the post (Figs 2B and 3). At no time during these procedures is the rotator cuff detached or a full-thickness tear created.

The coracoacromial ligament is reefed and not resected. Subacromial decompression is performed if necessary to achieve a type I acromion, generally resecting less than 5 mm of bone from the anterior



**FIGURE 2.** (A) A percutaneous suture banana lasso through the Neviaser portal is used to retrieve the sutures from the suture anchor. (B) After both the anterior and posterior sutures are passed through the bursal-sided tear, both sutures are tied securely over the bursal side of the rotator cuff, restoring the bursal side of the cuff to its anatomic location.

acromion. In the subset of PTBRCTs (in contrast to articular-sided tears), acromioplasty is routine.

Postoperatively, all patients undergo aggressive rehabilitation with early active motion. Pendulum exercises and full passive range of motion are started immediately, and active assisted motion is started 2 weeks postoperatively. Strength training is started at 4 weeks postoperatively. Sling use was discontinued at 4 weeks initially and at 2 weeks as our experience increased.

At intermediate-term follow-up ( $\geq 24$  months), all 15 patients had excellent results without complications, with a mean University of California, Los Angeles (UCLA) score of 33. All were able to participate in aggressive physical therapy immediately after surgery.

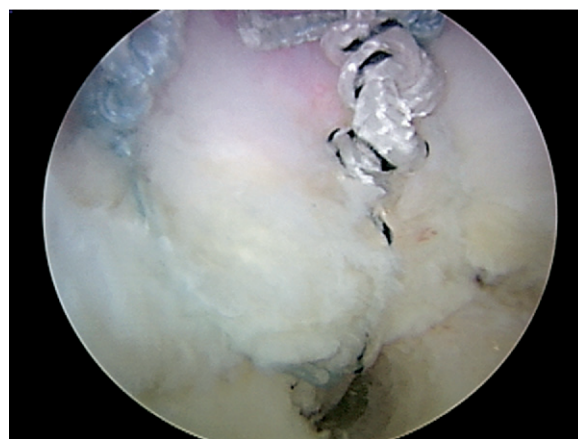
## DISCUSSION

There is a relative paucity of published results of PTBRCT treatment. A 1999 study by Weber<sup>3</sup> compared the results at 2 to 7 years' follow-up of 65 patients with partial-thickness tears treated with either acromioplasty and arthroscopic debridement or acromioplasty with mini-open repair. He reported a mean UCLA score of 31.6 in patients undergoing mini-open repair versus 22.7 in those undergoing arthroscopic debridement when both articular-sided and bursal-sided tears were included. Among the PTBRCT subgroup, he reported a mean UCLA score of 33.0 in those treated with mini-open repair versus 13.6 in those treated with arthroscopic debridement. Although the numbers of PTBRCTs in this study were small (3 were debrided and 5 were repaired), the disparity

in the outcome of debridement versus repair suggested that debridement is not adequate treatment for PTBRCTs.

Park et al.<sup>4</sup> reported satisfactory results in 86% of patients 2 years after arthroscopic acromioplasty and debridement of articular- and bursal-sided tears of less than 50%. Of note, they reported that the PTBRCTs fared significantly better with respect to pain score and function at 6 months but that the groups were not significantly different at 1 year and 2 years of follow-up. Although Park et al. did not classify the tears, they stated that all were 3 to 6 mm in depth, which would make them all grade 2A and 2B tears according to the classification system of Ellman.<sup>2</sup>

Cordasco et al.<sup>1</sup> reported results of arthroscopic subacromial decompression and debridement of partial-thickness tears that were in concordance with those of Weber<sup>3</sup> but differed from those of Park et al.<sup>4</sup> They showed that patients with PTBRCTs have a much higher rate of unsatisfactory outcomes than patients with partial-thickness articular-sided tears at 2 to 10 years' follow-up (mean, 4.5 years). In their study there was a 5% failure rate for grade 2A tears (2/44) versus a 38% failure rate in patients with grade 2B tears (3/8) ( $P = .02$ ). When grade 1A and 1B tears were included, the overall treatment failure rate for PTBRCTs was 29% (4/14), whereas the failure rate in the articular-sided tears was 3% (2/63) ( $P = .008$ ). Of the 8 patients in whom treatment failed, 4 (50%) had a pathologic condition on the bursal side. Of note, the authors stated that all of the failures in their study garnered no benefits from surgery and the failure was apparent immediately. Thus the lack of concordance with the study of Park et al. cannot be explained by the



**FIGURE 3.** PTBRCT after repair.

longer follow-up of the reports of Weber and Cordasco et al. On the basis of these data, Cordasco et al. state that they have begun to repair grade 2B partial-thickness tears.

For these reasons, we have lowered the threshold for repair of grade 2B (bursal-sided) tears at our hospital. We have performed this procedure on 15 patients with normal articular-sided rotator cuffs and at least an A0B2 or A0B3 pattern of tear (minimum thickness of 25% to 75%). All 15 patients treated with the described protocol exhibited fraying of the coracoacromial ligament and underwent acromioplasty and reefing of this ligament so that the extrinsic pathogenesis of the PTBRCTs could be addressed. In our limited series all 15 patients had excellent intermediate-term results ( $\geq 24$  months) without complications, with a mean UCLA score of 33. All were able to participate in aggressive physical therapy immediately after surgery.

The articular side of the rotator cuff experiences greater tension than the bursal side of the cuff.<sup>5</sup> In leaving the articular footprint intact, we accomplish 3 goals: the intact articular fibers act as an internal splint to protect the bursal-sided repair, a wide and anatomic footprint is recreated, and we are able to minimize any length-tension mismatch because the tissue is not excessively lateralized with repair. On the basis of our excellent results, along with the aggressive rehabilitation program, we believe that these goals are achieved.

It seems likely that, in our patients, the tendon debridement and repair were able to heal in a way that stabilized the insertional mechanism, thereby distributing the loads from muscle to bone in a way that prevented disproportionately large loads from being concentrated on the neighboring intact tendon fibers, which may be the cause of the reported poor results of debridement alone.

## CONCLUSIONS

Although longer follow-up is necessary, in our consecutive series of 15 patients with PTBRCTs, all have gone on to have excellent results with respect to pain relief and functional restoration.

## REFERENCES

1. Cordasco FA, Backer M, Craig EV, Klein D, Warren RF. The partial-thickness rotator cuff tear: Is acromioplasty without repair sufficient? *Am J Sports Med* 2002;30:257-260.
2. Ellman H. Diagnosis and treatment of incomplete rotator cuff tears. *Clin Orthop Relat Res* 1990;64-74.
3. Weber SC. Arthroscopic debridement and acromioplasty versus mini-open repair in the treatment of significant partial-thickness rotator cuff tears. *Arthroscopy* 1999;15:126-131.
4. Park JY, Yoo MJ, Kim MH. Comparison of surgical outcome between bursal and articular partial thickness rotator cuff tears. *Orthopedics* 2003;26:387-390.
5. Nakajima T, Rokuuma N, Hamada K. Histological and biomechanical characteristics of the supraspinatus tendon. *J Shoulder Elbow Surg* 1994;3:79-87.