



ELSEVIER

Contents lists available at ScienceDirect

The Journal of Arthroplasty

journal homepage: www.arthroplastyjournal.org

Primary Arthroplasty

Acetabular Placement Accuracy With the Direct Anterior Approach Freehand Technique

Melissa C. Soderquist, BS ^{a,*}, Ryan Scully, MD ^b, Anthony S. Unger, MD ^b^a Georgetown University School of Medicine, Washington, DC^b Department of Orthopedic Surgery, George Washington University, Washington, DC

ARTICLE INFO

Article history:

Received 3 February 2017

Received in revised form

5 April 2017

Accepted 7 April 2017

Available online 18 April 2017

Keywords:

total hip arthroplasty

direct anterior approach

acetabular cup placement

hip arthroplasty complications

post-operative dislocation

ABSTRACT

Background: Acetabular cup placement in total hip arthroplasty (THA) has been recognized as an important factor in operative success, and accurate cup placement has been the impetus for novel medical technologies.

Methods: This article examines the cup placement in 955 THAs using a freehand Direct Anterior Approach on a standard operating table. Acetabular anteversion and inclination were determined using the circle theorem. Measurements were divided into safe zone placement determined by Callanan et al as 5°–25° for anteversion and 30°–45° for inclination, as well as by Lewinnek et al as 5°–25° for anteversion and 30°–50° for inclination. Dislocation rate was determined and correlated to safe zone placement.

Results: Although technology has advanced for cup placement, this investigation shows that a freehand technique demonstrates 0.31% dislocation after THA with an accuracy of 85% for the Lewinnek safe zone and 61% for Callanan, potentially because of the sparing of the posterior hip capsule.

Conclusion: The direct anterior approach to the hip on a regular operating table is safe and reliable. Our results demonstrate improvement in cup positioning compared with other freehand techniques. Surgeon awareness and control of the position of the pelvis within space optimizes acetabular component accuracy and precision without the need for special equipment, such as intraoperative fluoroscopy.

© 2017 Elsevier Inc. All rights reserved.

Over the next 2 decades, a projected 572,000 primary total hip arthroplasties (THAs) are expected to be performed [1]. This growing demand for hip arthroplasty is occurring at a tumultuous time in health care, where surgical outcomes are measured with regard to cost-effectiveness, patient satisfaction, length of stay, and rate of complications. Nevertheless, the principles of a successful primary THA remain unchanged: symptom relief, stability, longevity, and functional range of motion. Although improvements in materials have increased the durability of the primary THA, obtaining stability and range of motion remain the responsibility of the surgeon. Alongside prosthetic joint infection, hip instability and dislocation remains a predominant cause for early (within

3 months) revision [2]. Although soft-tissue tensioning, femoral component position, and patient factors can affect stability, one of the most studied factors is acetabular component position.

In 1978, Lewinnek et al [3] defined the safe zone for acetabular component positioning as 5°–25° of anteversion and 30°–50° of abduction. Cup placement outside these parameters has been associated with an increased risk of dislocation. Others have corroborated these findings [4–6]. In addition to instability, acetabular component malposition can result in the following: polyethylene liner fracture, accelerated wear rates, pelvic osteolysis, impingement, limb length discrepancy, and diminished range of motion [7–10]. As such, the desire for precise and accurate cup placement has been the impetus for various novel technologies, such as fluoroscopic guidance, computer navigation, patient-specific instrumentation, and robotics [1,11,12]. Although these technologies have been shown to improve accuracy and precision (less variance) for acetabular component placement, the cost, radiation exposure, need for well-trained operating room staff, and setup time remain significant concerns [13,14].

The effect of surgical approach on freehand acetabular component placement has been studied. The term “freehand” used here

This research was supported by the Alma and Joseph Gildenhorn Fund.

One or more of the authors of this paper have disclosed potential or pertinent conflicts of interest, which may include receipt of payment, either direct or indirect, institutional support, or association with an entity in the biomedical field which may be perceived to have potential conflict of interest with this work. For full disclosure statements refer to <http://dx.doi.org/10.1016/j.arth.2017.04.011>.

* Reprint requests: Melissa C. Soderquist, BS, Georgetown University School of Medicine, 3900 Reservoir Road NW, Washington, DC 20007.

<http://dx.doi.org/10.1016/j.arth.2017.04.011>

0883-5403/© 2017 Elsevier Inc. All rights reserved.

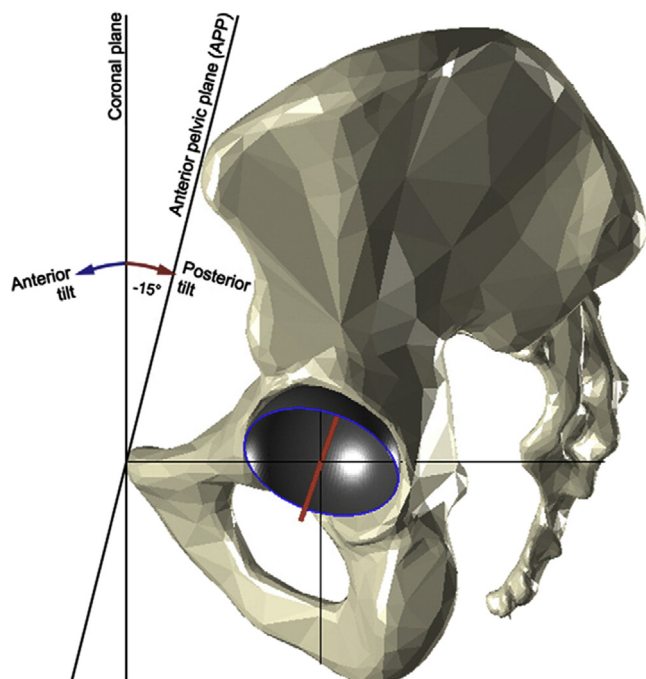


Fig. 1. The surgeon adjusts the pelvic position using the rectangular sacral bump to bring the anterior pelvic plane collinear with the coronal plane. This aspect of the direct anterior approach using a regular table facilitates surgeon awareness of the position of the pelvis in space and therefore precise and accurate acetabular cup placement [15].

indicates that surgical placement of the acetabular cup is accomplished without a specialized operating table or the use of image-guidance techniques. We believe that performing the approach on a standard operating table allows the surgeon to place the pelvis in a known position in space and with respect to the coronal plane. This investigation seeks to determine if acetabular component placement accomplished using the direct anterior approach on a standard operating table without fluoroscopy can generate a comparable accuracy and outcome on the basis of dislocation to those techniques using a specialized operating table and image guidance.

Methods

Using the hospital medical records database, 992 THAs performed by a single surgeon (ASU) from January 2010 through May 2016 were identified. All surgeries were performed on a regular operating table with standard instruments using the direct anterior approach. Cementless acetabular and femoral components were used for all patients, unless otherwise indicated for specific patients. The medical records database was used to obtain demographic information for each patient, including gender, body mass index (BMI), age, and laterality of operated hip. All patients involved in this investigation had the diagnosis of osteoarthritis with unilateral hip arthritis. All patients were required to have a digital 6-week postoperative radiograph to measure acetabular cup inclination and anteversion angles. Thirty-seven patients were excluded owing to implant selection (modular dual mobility, Birmingham hip resurfacing), femoral neck fractures, Parkinson's disease, or acetabular dysplasia. A total of 74 hips did not have data for BMI and were therefore excluded from statistical analysis for the BMI portion of the study. A total of 955 hips were included in analysis, of which 597 (62.5%) were female and 358 (37.5%) were male. The mean patient age was 71.2 ± 9.8 years (range, 26–97 years), and the mean BMI was 26.3 ± 4.9 kg/m² (range, 15.4–46.5 kg/m²).

Surgical Procedure

The patient is placed supine on the operating table. A 2-inch thick sacral pad was used in all patients, keeping the anterior pelvic plane of the patient and coronal plane collinear with the operating table. This positioning of the acetabular component with respect to the coronal plane can be visualized in Figure 1 [15]. The value of this technique is to allow adipose tissue to fall away from the hip to facilitate better prepping and draping of the patient. The pad is 16 inches wide by 2.5 feet long by 2 inches thick, fitting across the patients' sacrum and does not rotate the pelvis. An 8- to 10-cm incision is made over the tensor fascia lata (TFL) muscle belly. The superficial fascia of the TFL is incised and muscle retracted posterolaterally. The interval between the sartorius and TFL is bluntly developed. The lateral femoral circumflex vessels are identified and cauterized. The deep interval is developed between the rectus femoris and greater trochanter, curving medially proximally to avoid the abductor musculature. The reflected head of the rectus femoris is released, and a capsulotomy is made. The femoral neck osteotomy is performed at the level of the greater trochanter base ("saddle.") The acetabulum is reamed sequentially, and final acetabular component is placed on a straight handle with attention to the handle position relative to the patient's body to assess appropriate anteversion and inclination. Optimal position was targeted as 15° anteversion and 40° inclination. The femur is then prepared with sequential broaches. Trial components are placed before final component implantation.

Measurements

The acetabular cup inclination and anteversion angles were measured by an independent observer on a single anteroposterior (AP) hip radiograph taken 6 weeks postoperatively in the Merge PACS system using the circle theorem, validated by others [16]. Using the circle theorem, the following geometry of the hip is outlined as seen in Figure 2.

This geometry then shows that the angle of version can be calculated using the formula $version = \cos^{-1} \left(\frac{line\ 5}{line\ 6} \right)$ [17]. When using the direct anterior approach in the supine position on a standard operating room table, there is reassurance that the placement of the acetabulum is anteverted, which will be made by the parallax changes from the AP hip position to the AP pelvis position. Anteversion angle measured from AP pelvis to AP hip increases, which confirms that the cup is anteverted [8]. The inclination angle was measured by using the transischial line as a reference to determine the lateral inclination placement of the acetabulum.

To ensure accuracy and repeatability of measurement by the independent observer, a set of 10 randomly selected AP pelvic radiographs were each read until the independent observer was within 1 standard deviation of the previous reading in the measurement 3 times. All measurements in this investigation were completed by a single observer.

The measurements of anteversion and inclination were divided into different safe zones as defined by Lewinnek et al [3] and Callanan et al [7]. The Lewinnek safe zone is defined as an anteversion from 5° to 25° and an inclination from 30° to 50°. The Callanan safe zone is defined as an anteversion from 5° to 25° and an inclination from 30° to 45°. The precision and consistency of cup placement over time was determined and analyzed using a regression line of inclination values, allowing examination of the spread of residuals around this line and the changes in cup placement over time.

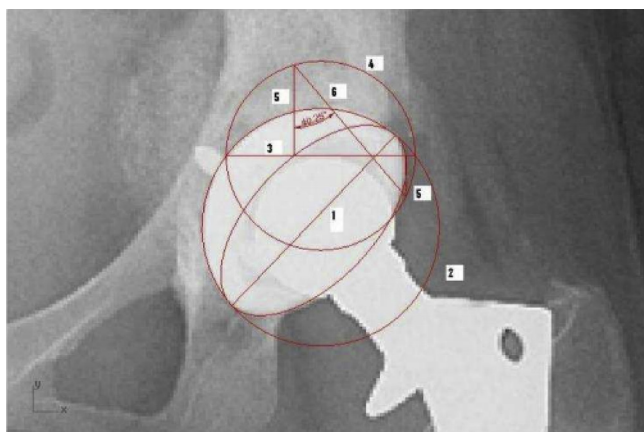


Fig. 2. The geometry of the hip outlined using the circle theorem, which can be used to calculate acetabular version [16,17].

Statistical Analysis

The impact of laterality of the surgery was determined by performing a chi-square analysis of the side the surgery was performed on and the placement inside the safe zone by a right-handed surgeon. A total of 525 (55%) right THAs and 430 (45%) left THAs were performed. In addition, the chi-square and the Fisher exact tests were used to examine the association of safe zone variables with gender, and the 2-tailed between-groups *t* tests were used to examine association of safe zone variables with age and BMI. Pelvic obliquity was also measured, and the association between pelvic obliquity and placement inside the safe zone was determined. Dislocations after the operation were recorded. Dislocations were determined by patient follow-up appointments at 2 weeks, 6 weeks, 3 months, and 1 year.

Results

The average inclination and anteversion angles for the 955 hips included in the study were $43.5^\circ \pm 7^\circ$ and $10.0^\circ \pm 3.1^\circ$, respectively. Inclination angles ranged from 21° to 66° , and anteversion angles ranged from 3.1° to 19.8° . There were 813 (85%) acetabular cups that were placed within the safe zone for both inclination and anteversion based on the safe zones defined by Lewinnek et al [3] and 580 (61%) acetabular cups that were placed within the safe zone for both inclination and anteversion based on the safe zones defined by Callanan et al [7]. Eight hundred twenty-five (86%) hips were placed in the safe zone for inclination defined by Lewinnek et al and 589 (62%) hips were placed in the safe zone for inclination defined by Callanan et al; 941 (99%) hips were placed in the safe zone for anteversion defined by Lewinnek et al and Callanan et al. The distribution of inclination and anteversion angles is shown in Table 1. Scatter plots of inclination and anteversion angles with the safe zones denoting optimal acetabular cup placement defined by Lewinnek et al and Callanan et al are shown in Figures 3 and 4.

The pelvic cup inclination angle over time is shown in Figure 5. There is a low negative correlation between pelvis cup inclination and date ($r = -0.29$), indicating that cup inclination decreased slightly over time. The R^2 value was calculated to be 0.084 ($P < .0001$), and the pelvis cup inclination can be characterized by the following: pelvis cup inclination = $-0.003305 \times \text{date} + 108.56208$. This equation allows for prediction of the pelvis cup inclination angle based on the date in which it was performed. The Pearson correlation between the absolute value of the distance from the line and the date is -0.06 ($P = .61$), meaning that precision in placement

Table 1
Distribution of Inclination and Anteversion Angles for Hips Included in the Study.

Angle Ranges	Number of Hips (n = 955)	% of Total
Inclination		
20°–25°	3	0.3
25°–30°	18	1.9
30°–35°	113	11.8
35°–40°	239	25.0
40°–45°	315	33.0
45°–50°	296	31.0
50°–55°	132	13.8
55°–60°	47	4.9
60°–65°	17	1.8
65°–70°	3	0.3
Anteversion		
0°–5°	18	1.9
5°–10°	499	52.3
10°–15°	376	39.4
15°–20°	62	6.5
20°–25°	0	0.0

of the acetabular cup within the safe zone for inclination is increasing over time.

The association of placement within the safe zone of the acetabular cup for right- and left-sided hip arthroplasties by a right-handed surgeon is displayed in Table 2. In the table, “Both” indicates that the acetabular cup was placed within the safe zone for inclination and anteversion, whereas “Neither” indicates that the acetabular cup was not placed within the safe zone for inclination or anteversion. In addition, the association of gender and placement within the safe zone is shown in Table 3. The placement within the safe zone by BMI is shown in Table 4. BMI is separated into categories of <34.99 , 35–40, and >40 kg/m². Cup malposition for inclination occurred more frequently in patients with a higher BMI, where the percentage of malpositioned cups was 13% for BMIs <34.99 kg/m², 13% for BMIs from 35 to 40 kg/m², and 33% for BMIs >40 kg/m² for a safe zone defined by Lewinnek et al. Data for the safe zone determined by Callanan et al demonstrate cup malposition for inclination being 37% for BMIs <34.99 kg/m², 28% for BMIs from 35 to 40 kg/m², and 58% for BMIs >40 kg/m². Cup malposition for version did not occur more frequently over the range of patient

Lewinnek Safe Zone (n=955)

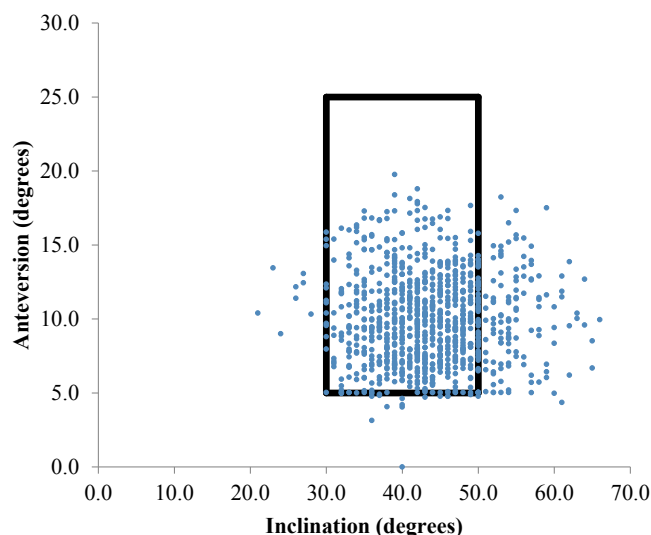


Fig. 3. A scatter plot of the hip inclination and anteversion angles, showing those placed within the safe zone defined by Lewinnek et al [3].

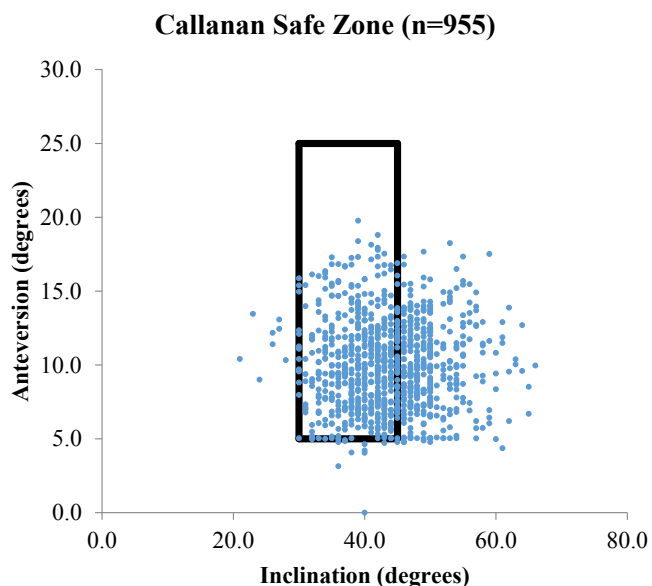


Fig. 4. A scatter plot of the hip inclination and anteversion angles, showing those placed within the safe zone defined by Callanan et al [7].

BMI. Males were significantly more likely than females to have safe zone landings based on inclination and version defined by both Lewinnek et al and Callanan et al. Patients with placement inside the safe zone were significantly younger than those malpositioned, based on inclination defined by Lewinnek et al and Callanan et al.

The total number of dislocations after operation was 3 of the 955 patients (0.31%) included in the study (Table 5). Two of these dislocations were left sided and 1 was right sided. Dislocations were determined based on follow-up appointments with patients seen postoperatively at 2 weeks, 6 weeks, 3 months, and 1 year. The average inclination angle of those hips that dislocated was $46.7^\circ \pm 5.5^\circ$, and the average anteversion angle was $6.9^\circ \pm 2.2^\circ$. One of these hips was placed outside the safe zone for inclination defined by Lewinnek et al and 2 of these hips were placed outside the safe zone for inclination defined by Callanan et al. All 3 hips were placed

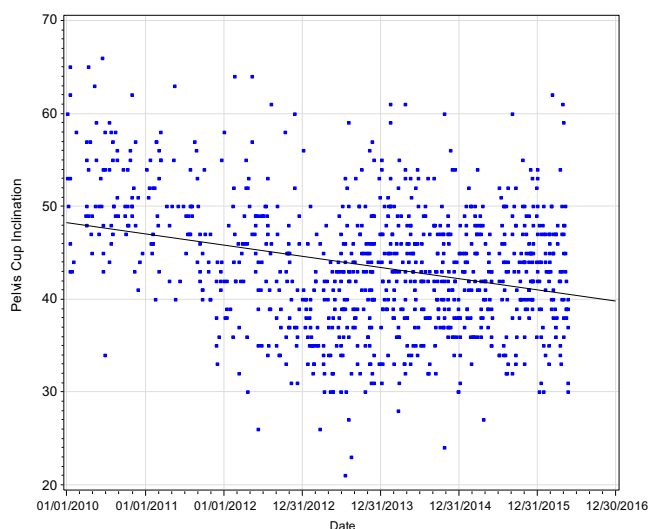


Fig. 5. A scatter plot of the pelvis cup inclination placement over the duration of the study. The dispersion is decreasing with time, suggesting that precision is increasing.

Table 2

Placement Inside the Safe Zone for Right-Sided and Left-Sided Hip Arthroplasties by a Right-Handed Surgeon. Both Indicates That the Acetabular Cup Was Placed Within the Safe Zone for Inclination and Anteversion, Whereas Neither Indicates That the Acetabular Cup Was Not Placed Within the Safe Zone for Inclination or Anteversion.

Safe Zone Variable	Laterality		P Value
	Right (n = 525), n (%)	Left (n = 430), n (%)	
Lewinnek			
Inclination	475 (90.5)	350 (81.4)	<.0001
Anteversion	516 (98.3)	425 (98.8)	.48
Both	467 (89.1)	346 (80.5)	.0002
Neither	2 (0.4)	1 (0.2)	.68
Callanan			
Inclination	381 (72.6)	208 (48.4)	<.0001
Anteversion	516 (98.3)	425 (98.8)	.48
Both	377 (71.8)	203 (47.3)	<.0001
Neither	4 (0.8)	1 (0.2)	.39

within the safe zones defined by Lewinnek et al and Callanan et al for anteversion. Of these dislocations, 1 required revision surgery.

Although measuring inclination angles on AP hip radiographs, it was noted that some of the pelvises demonstrated obliquity, which impacted the inclination angle measured and placement within the safe zone. The number of inclination angles that measured $>50^\circ$ was 121, and 88 (70%) of these displayed pelvic obliquity.

Discussion

In our series, the acetabular cup was placed 86% of the time within the safe zone defined by Lewinnek et al and 61% of the time within the safe zone defined by Callanan et al. This is due to the difference in optimal inclination angles determined by Lewinnek et al (30° - 50°) and Callanan et al (30° - 45°). The percentage of optimally positioned cups has shown improvement over other reported series of freehand techniques investigated in the study by Callanan et al where 47% of acetabular cups were placed in the safe zone using different approaches to THA [7]. In addition, cup placement regarding inclination became more precise over time, which demonstrates the evolution of surgeon efficacy with repetition and experience. The version placement did not significantly change over time. We also believe that the degree of accuracy and precision afforded by the direct anterior approach is a major advantage and is largely due to consistency and surgeon awareness in patient positioning. Over the past decade, there has been a greater focus in improving acetabular placement. Acetabular component accuracy from the lateral decubitus position has generally been inferior, with safe zone landing rates ranging from 59% to 72% [7,18]. We believe that an explanation for the discrepancy is in part due to loss of surgeon “pelvic proprioception” in the lateral decubitus position, as compared with supine position. Furthermore, Grammatopoulos et al [19] demonstrated variation in

Table 3

Placement Inside the Safe Zone Association With Gender.

Safe Zone Variable	Males (n = 358), n (%)	Females (n = 597), n (%)	P Value
Lewinnek			
Inclination	325 (90.8)	500 (83.8)	.0022
Anteversion	358 (100)	583 (97.7)	.0035
Both	325 (90.8)	488 (81.9)	.0002
Neither	0 (0)	3 (0.5)	.3
Callanan			
Inclination	242 (67.6)	347 (58.1)	.0036
Anteversion	358 (100)	583 (97.7)	.0035
Both	241 (67.5)	339 (56.8)	.001
Neither	0 (0)	5 (0.8)	.16

Table 4
BMI Separated Into Categories of <34.99, 35–40, and >40 kg/m² With Placement Inside the Safe Zones Defined by Lewinnek et al [3] and Callanan et al [7].

Safe Zone Variable	BMI		
	<34.99 kg/m ² (n = 830), n (%)	35–40 kg/m ² (n = 39), n (%)	>40 kg/m ² (n = 12), n (%)
Lewinnek			
Inclination	726 (87)	34 (87)	8 (67)
Anteversion	817 (98)	38 (97)	12 (100)
Both	716 (86)	33 (85)	8 (67)
Neither	3 (1)	0 (0)	0 (0)
Callanan			
Inclination	522 (63)	28 (72)	5 (42)
Anteversion	817 (98)	38 (97)	12 (100)
Both	514 (62)	27 (69)	5 (42)
Neither	5 (1)	0 (0)	0 (0)

BMI, body mass index.

patient position and nearly 10° of motion from the time of positioning to final component implantation. Saxler et al [20] reported on their experience with freehand cup placement in the supine position via the anterolateral approach. They found a 25.7% rate of safe zone placement. Hassan et al [21] reported 58% of cups positioned within the Lewinnek safe zone using the direct lateral approach and lateral decubitus positioning. Their group pointed to the tendency of the pelvis to sway forward and backward in the sagittal plane during surgery and suspected this as a component of the inaccuracy. Despite 58% accuracy, none of the 50 hips evaluated in this series dislocated.

In addition, variability of the position of the pelvis is not only affected by positioning on the operating table but by patient-specific factors. Pelvic tilt is the compensatory mechanism by which patients attempt to maintain a normal sagittal alignment. In patients with thoracic kyphosis or loss of lumbar lordosis, the pelvis extends backward over the hips increasing pelvic tilt to decrease sagittal imbalance. This commonly occurs as a normal process of aging and spondylosis. Although pelvic tilt is a dynamic, positional compensatory parameter, the spinopelvic relationship is also defined by morphologic parameters such as pelvic incidence and sacral slope. The clinical significance of this relationship for the arthroplasty surgeon was highlighted by Grammatopoulos et al [19,22], who measured changes in acetabular component orientation between the standing and the supine positioning. Sitting-to-standing increased anteversion and inclination by 4.5° and 1.4°, respectively. Summarized by Grammatopoulos et al, who stated “the current description of ‘safe zone’ does not take into account the influence of patient position on acetabular orientation.” Jar-amaz et al [12] showed that the cup flexion amount between the lateral decubitus and supine positions of the patient can range between 0° and 20°. Each movement of the anterior pelvic plane intraoperatively alters the tilt of the pelvis and, therefore, has been shown to alter the position of the implants [23]. Failure to recognize and control for these variables may decrease the accuracy and reliability of component placement, which can lead to adverse postoperative outcomes requiring revision surgery.

Table 5
Dislocations After Surgery Are Displayed With the Side the Surgery Was Performed, the Angles of Placement of the Acetabular Cup, the Number of Dislocations, Whether a Revision Surgery Was Required, and the Circumstance of the Dislocation.

Dislocations (n = 3)					
Side	Inclination	Anteversion	No. of Dislocations	Revision Required	Circumstance
Left	52°	6.3°	2	No	Posterior dislocations with many prior problems
Left	47°	5°	1	Yes	Dislocation followed fall
Right	41°	9.3°	1	No	

The placement rate of 61% in this investigation within the safe zone for both inclination and anteversion is comparable or better with regard to recently published results by others also using a freehand approach [7,20,24–28]. These comparisons are summarized in Table 6.

We also examined patient factors and their apparent effect on cup placement. Interestingly, laterality impacted cup accuracy, with right-sided surgery having a higher incidence of safe zone landings. The surgeon in this study is right-handed and placement within the safe zone defined by Lewinnek et al for the right hip was 89.1% and the left hip was 80.5%. Placement within the safe zone defined by Callanan et al for the right hip was 71.8% and the left hip was 47.5%. This could be explained by the position of the surgeon when placing the acetabulum; performing the procedure on the side of the dominant hand may allow for better maneuverability.

The association between gender and cup placement was also analyzed. Placement within the safe zone defined by Lewinnek et al for males was 90.8% and for females was 81.9%. Placement within the safe zone defined by Callanan et al for males was 67.5% and for females was 56.8%. Results also show that malpositioned cups for inclination occurred more frequently in older patients, where the mean age of those with malpositioned inclined cups defined by Lewinnek et al was 73.4 years and the mean age of those within the safe zone was 70.9 years. Finally, the effect of BMI on cup placement was analyzed. Cup malposition for inclination occurred more frequently in patients with a higher BMI, where the percentage of malpositioned cups increased from 13% in patients with BMIs <34.99 kg/m² to 33% in patients with BMIs >40 kg/m² for the safe zone defined by Lewinnek et al. Cup malposition for the safe zone defined by Callanan et al shows 37% malposition in patients with BMIs <34.99 kg/m² to 58% malposition in patients with BMIs >40 kg/m². Cup malposition for version did not occur more frequently over the range of patient BMIs. Todkar [25] demonstrated that BMI does not play a role in placement of the acetabular cup, whereas others have determined that a higher BMI led to a higher incidence of acetabular cup malposition [7].

Pelvic obliquity was observed in 70% patients whose cup inclination angle exceeded 50°. Pelvic obliquity can be caused by contracture at the hip, limb length discrepancy, or structural scoliosis [29]. Pelvic obliquity was examined for on postoperative imaging based on an inclination angle measuring >50°. If this was the case, the X-ray was reviewed for obliquity, and if the pelvis was not straight, a new measurement was obtained to correct for obliquity and to determine if this obliquity impacted safe zone placement of the acetabular cup. The association and significance of pelvic obliquity with cup position warrants further research, but considering the findings from our study, we recommend surgeon awareness of pelvic obliquity during preoperative planning as an added measure for ensuring desirable cup placement.

Performing the direct anterior approach for primary THA on a regular operating table is supported by this investigation through the accuracy of acetabular cup placement and low dislocation rate (0.31%). Boettner et al [30] demonstrated 100% accuracy in acetabular cup placement when using computed

Table 6
Comparison of Results to Recent Literature. All These Studies Investigated a Freehand Surgical Approach.

Authors	Number of Hips	Surgical Approach Investigated	Average Inclination Angle	Average Version Angle	% of Optimally Positioned Cups
Bosker et al [26]	200	Posterolateral approach and anterolateral approach	49.7° ± 6.7°	16° ± 8.1°	85.2% (30°–50° inclination criteria), 82.7% (5°–25° anteversion criteria), 70.5% combined, and 21.5% (±5°)
Callanan et al [7]	1952	Posterolateral approach, direct lateral approach, anterolateral approach, minimally invasive surgical approach	42.2° ± 6.8° (21°–73°)	12.7° ± 7.4° (–17° to 43°)	62% (30°–45° inclination), 79% (5°–25° anteversion criteria), and 47% combined
Leichtle et al [27]	950		48.7° ± 7° (28°–75°)	18.6° ± 9° (–9° to 50°)	22.7% (45° ± 5° inclination), 82.7% (20° ± 5° version criteria), and 70.5% (±10°)
Myers et al [28]	64 (BHR)	Posterior approach and lateral approach	37.5° (56°–50°) for posterior approach and 43° (30°–56°) for lateral approach		
Reize et al [24]	85	Lateral transgluteal approach	45.8° ± 10.1° (23°–71.5°)	27.3° ± 15° (–23.5° to 59°)	41% (30°–50° inclination, 5°–25° anteversion criteria)
Saxler et al [20]	105		44.5°, 46.8°, and 44° for healthy, overweight, and obese	11.6°, 12.2°, 10.7° for healthy, overweight, and obese	25.7% (30°–50° inclination, 5°–25° anteversion criteria)
Todkar [25]	111			10° ± 3.1°	
Soderquist et al ^a	955	Direct anterior approach	43.5° ± 7.0°		62% (30°–45° inclination), 99% (5°–25° anteversion criteria), and 61% combined

BHR, Birmingham hip resurfacing.

^a Present study.

tomography-guided positioning through a direct anterior approach. Furthermore, Matta et al [31] reported excellent results on a series of 494 primary THAs. Using a modified Hueter direct anterior approach, a specialized orthopedic table, and C-arm fluoroscopy, Matta et al reported 96% inclination accuracy and 93% anteversion accuracy. The dislocation rate was 0.61%. However, alternate studies have shown that although a safe zone for acetabular cup placement has been established, placing the acetabular cup within the safe zone does not prevent dislocation [32]. Similarly, other studies have shown a low dislocation rate despite placement outside the safe zone [21]. This investigation demonstrates the advantage of the direct anterior approach in maintaining dynamic stability by sparing the posterior hip capsule and short external rotators. A freehand approach using anatomic landmarks allows the surgeon to customize the surgery as well as reduce the cost and hassle that may be associated with image guidance and related navigational technology to orient the cup [33]. Additional research is required to determine the difference in cup placement accuracy in the direct anterior approach using a specialized table, fluoroscopy, and a standard operating table. At this point in time, there is much debate in the literature about what the ideal cup placement is. Functional cup positioning using patient-specific factors is now being explored as a way of addressing this placement.

This study has several limitations. The data were collected by an independent observer, which introduces uncertainty because measurements were made manually and not calculated using a computer algorithm. Second, our investigation is focused on 1 high-volume surgeon's performance using the anterior approach to THA, which may not reflect other surgeons' ability to place the acetabular cup in the safe zone without comparable experience or navigational assistance. Finally, incidence of dislocation is only a single measure of outcome. Instability can result despite a well-placed cup, and similarly, patients with a well-placed cup may have instability.

Conclusion

The direct anterior approach to the hip on a regular operating table is safe and reliable. Our results demonstrate improvement in cup positioning compared with other freehand techniques. Surgeon awareness and control of the position of the pelvis within space optimizes acetabular component accuracy and precision without the need for special equipment, such as intraoperative fluoroscopy. Further studies are required to further characterize the acetabular safe zone, as its definition and clinical relevance has been challenged since the landmark study by Lewinnek et al. Finally, with the mounting pressure placed on surgeons for fiscal efficiency, further studies are warranted to compare the cost-effectiveness of the direct anterior approach with and without special equipment.

Acknowledgments

The authors thank their colleagues, Richard Amdur, PhD, and Xiangyu Kuang, from George Washington University for assistance and expertise with statistical analysis.

References

- [1] El Bitar YF, Jackson TJ, Lindner D, Botser I, Stake C, Domb B. Predictive value of robotic-assisted total hip arthroplasty. *Orthopedics* 2015;38:31–7.
- [2] American Joint Replacement Registry. Annual report. Rosemont, IL; 2016.
- [3] Lewinnek GE, Lewis JL, Tarr R, Compere C, Zimmerman J. Dislocations after total hip-replacement arthroplasties. *J Bone Joint Surg Am* 1978;60:217–20.

- [4] Biedermann R, Tonin A, Krismer M, Rachbauer F, Eibl G, Stockl B. Reducing the risk of dislocation after total hip arthroplasty: the effect of orientation of the acetabular component. *J Bone Joint Surg Br* 2005;87:762–9.
- [5] Jolles B, Zangger P, Leyvraz P. Factors predisposing to dislocation after primary total hip arthroplasty: a multivariate analysis. *J Arthroplasty* 2002;17:282–8.
- [6] McCollum DE, Gray WJ. Dislocation after total hip arthroplasty causes and prevention. *Clin Orthop Relat Res* 1990;261:159–70.
- [7] Callanan MC, Jarrett B, Bragdon CR, Zurakowski D, Rubash H, Freiberg A. The John Charnley Award: risk factors for cup malpositioning: quality improvement through a joint registry at a tertiary hospital. *Clin Orthop Relat Res* 2011;469:319–29.
- [8] Tannast M, Langlotz U, Siebenrock K, Wiese M, Bernsmann K, Langlotz F. Anatomic referencing of cup orientation in total hip arthroplasty. *Clin Orthop Relat Res* 2005;436:144–50.
- [9] Kennedy J, Rogers W, Soffe K, Sullivan R, Griffen D, Sheehan L. Effect of acetabular component orientation on recurrent dislocation, pelvic osteolysis, polyethylene wear, and component migration. *J Arthroplasty* 1998;13:530–4.
- [10] Parvizi J, Sharkey PF, Bissett GA, Rothman R, Hozack W. Surgical treatment of limb-length discrepancy following total hip arthroplasty. *J Bone Joint Surg Am* 2003;85:2310–7.
- [11] Dorr LD, Wolf AW, Chandler R, Conaty J. Classification and treatment of dislocations of total hip arthroplasty. *Clin Orthop Relat Res* 1983;173:151–8.
- [12] Jaramaz B, DiGioia III AM, Blackwell M, Nikou C. Computer assisted measurement of cup placement in total hip replacement. *Clin Orthop Relat Res* 1998;354:70–81.
- [13] Kajino Y, Kabata T, Maeda T, Iwai S, Kuroda K, Tsuchiya H. Does degree of the pelvic deformity affect the accuracy of computed tomography-based hip navigation? *J Arthroplasty* 2012;27:1651–7.
- [14] Kanawade V, Dorr LD, Banks SA, Zhang Z, Wan Z. Precision of robotic guided instrumentation for acetabular component positioning. *J Arthroplasty* 2015;30:392–7.
- [15] Maratt JD, Esposito CI, McLawhorn AS, Jerabek S, Padgett D, Mayman D. Pelvic tilt in patients undergoing total hip arthroplasty: when does it matter? *J Arthroplasty* 2015;30:387–91.
- [16] Moretti V, Thormeyer J, Chmell S. Using the circle theorem to estimate acetabular version from a single antero-posterior hip radiograph. *Bone Joint J Orthop Proc Suppl* 2014;96:46.
- [17] Pradhan R. Planar anteversion of the acetabular cup as determined from plain anteroposterior radiographs. *Bone Joint J* 1999;81:431–5.
- [18] Minoda Y, Kadowaki T, Kim M. Acetabular component orientation in 834 total hip arthroplasties using a manual technique. *Clin Orthop Relat Res* 2006;445:186–91.
- [19] Grammatopoulos G, Pandit HG, da Assuncao R, Taylor A, McLardy-Smith P, De Smet K. Pelvic position and movement during hip replacement. *Bone Joint J* 2014;96:876–83.
- [20] Saxler G, Marx A, Vandeveld D, Langlotz U, Tannast M, Wiese M, et al. The accuracy of free-hand cup positioning—a CT based measurement of cup placement in 105 total hip arthroplasties. *Int Orthop* 2004;28:198–201.
- [21] Hassan DM, Johnston GH, Dust WN, Watson G, Dolovich AT. Accuracy of intraoperative assessment of acetabular prosthesis placement. *J Arthroplasty* 1998;13:80–4.
- [22] Grammatopoulos GM, Chen M, Langton D, Pandit H, Murray D, Gill H. The effect of pelvic tilt on acetabular component orientation in hip arthroplasty—a radiological analysis using EBRA. *ORS* 2011.
- [23] Lembeck B, Mueller O, Reize P, Wuelker N. Pelvic tilt makes acetabular cup navigation inaccurate. *Acta Orthop* 2005;76:517–23.
- [24] Reize P, Geiger EV, Suckel A, Rudert M, Wulker N. Influence of surgical experience on accuracy of acetabular cup positioning in total hip arthroplasty. *Am J Orthop (Belle Mead NJ)* 2008;37:360–3.
- [25] Todkar M. Obesity does not necessarily affect the accuracy of acetabular cup implantation in total hip replacement. *Acta Orthop Belg* 2008;74:206–9.
- [26] Bosker B, Verheyen C, Horstmann W, Tulp N. Poor accuracy of freehand cup positioning during total hip arthroplasty. *Arch Orthop Trauma Surg* 2007;127:375–9.
- [27] Leichtle U, Gosselke N, Wirth CJ, Rudert M. Radiologic evaluation of cup placement variation in conventional total hip arthroplasty. *Rofo* 2007;179:46–52.
- [28] Myers G, Morgan D, McBryde C, O'Dwyer K. Does surgical approach influence component positioning with Birmingham hip resurfacing? *Int Orthop* 2009;33:59–63.
- [29] Winter RB, Pinto WC. Pelvic obliquity: its causes and its treatment. *Spine* 1986;11:225–34.
- [30] Boettner F, Zingg M, Emara AK, Waldstein W, Faschingbauer M, Kasperek MF. The accuracy of acetabular component position using a novel method to determine anteversion. *J Arthroplasty* 2017;32:1180–5.
- [31] Matta JM, Shahrdrar C, Ferguson T. Single-incision anterior approach for total hip arthroplasty on an orthopaedic table. *Clin Orthop Relat Res* 2005;441:115–24.
- [32] Seagrave KG, Troelsen A, Malchau H, Husted H, Gromov K. Acetabular cup position and risk of dislocation in primary total hip arthroplasty: a systematic review of the literature. *Acta Orthop* 2017;88:10–7.
- [33] Moskal JT, Capps SG, Scanelli JA. Improving the accuracy of acetabular component orientation: avoiding malpositioning: AAOS exhibit selection. *J Bone Joint Surg Am* 2013;95:761–810.