

# Vasculopathy of Small Muscular Arteries in Pediatric Patients After Bone Marrow Transplantation

DENA M. SELBY, MD, JONAS R. RUDZKI, MS, ELIEL S. BAYEVER, MD,  
AND ROMA S. CHANDRA, MD

**Bone Marrow Transplant (BMT)** is a critical therapeutic intervention for a variety of diseases occurring in the pediatric patient. Complications of allogeneic BMT include graft-versus-host disease (GVHD), infection, drug toxicity, thrombotic microangiopathy, and veno-occlusive disease. With solid organ transplantation, chronic vascular rejection has emerged as a major factor limiting long-term survival of the graft. We present a vasculopathy of small muscular arteries in 6 patients after allogeneic BMT. Cases include 4 boys and 2 girls ranging in age from 4 months to 13 years with full or partial human leukocyte antigen matching. Five of the 6 transplants were from related donors. The vasculopathy occurred 13 to 418 days after transplant and was noted in surgical specimens (2) and at autopsy (4). It was seen in the gastrointestinal tract and lung in 3 cases each. Vascular changes in small muscular arteries include concentric intimal or medial hyperplasia with luminal narrowing, prominent myxoid change, extravasated red blood cells, and presence of some foamy histiocytes with no evidence of thrombotic microangiopathy.

Vasculopathy contributed to intestinal compromise requiring surgical intervention 3 times in 1 patient, and diffuse alveolar damage

Bone marrow transplant (BMT) is an important therapeutic intervention for several forms of cancer as well as some inherited metabolic and hematologic diseases in pediatric patients. Unfortunately, the efficacy of the procedure is often tempered by a number of severe reactions to the transplant itself, and/or the pre- and posttransplant regimens. A rare type of obliterative arteriopathy seen in postBMT patients represents a newly identified complication of the procedure, whose understanding may contribute to the knowledge base behind both bone marrow and solid organ transplantation. This vasculopathy appears distinctive, while at the same time possesses some characteristics similar to accelerated-graft atherosclerosis in cardiac transplant patients and chronic rejection of renal, lung, and liver allografts, as well as features seen in thrombotic microangiopathies (TMA) such as thrombotic thrombocytopenic purpura (TTP) and hemolytic-uremic syndrome (HUS).

with hemorrhage in another. All 6 patients are dead. The cause of this unusual vasculopathy present in patients after BMT is likely to be multifactorial, involving effects of irradiation, chemotherapy, cyclosporine, and GVHD. Together these may create a negative synergy which produces an obliterative arteriopathy that should be recognized as a pathological entity and may be a harbinger of a poor prognosis. *HUM PATHOL* 30:734-740. Copyright © 1999 by W.B. Saunders Company

*Key words:* vasculopathy, microangiopathy, chronic rejection, bone marrow transplant, infant and child.

*Abbreviations:* BMT, bone marrow transplant; TMA, thrombotic microangiopathies; TTP, thrombocytopenic purpura; HUS, hemolytic-uremic syndrome; HLA, human leukocyte antigen; Ig, immunoglobulin; GI, gastrointestinal; GVHD, graft-versus-host disease; ALL, acute lymphoblastic leukemia; CMV, cytomegalovirus; SCIDS, severe combined immunodeficiency syndrome; ARDS, adult respiratory distress syndrome; TBI, total body irradiation; CsA, cyclosporine; IL-2, interleukin-2; ET, endothelin; smc, smooth muscle cell contraction; CVR, chronic vascular rejection.

## MATERIALS AND METHODS

The 6 cases presented were retrieved from the files of the Department of Anatomic Pathology at Children's National Medical Center and consisted of 4 surgical pathology specimens representing 2 patients (3 separate small intestinal resections from 1 patient, and 1 lung wedge biopsy specimen from another) and 4 autopsied patients (from a database of 17 autopsied patients who were status post-BMT). The vasculopathy was an unexpected post mortem finding in the 4 autopsied patients, involving the gastrointestinal tract (2 cases) or the lungs (2 cases). Clinical histories of each of these patients were reviewed with focus on human leukocyte antigen (HLA) homology, pre- and posttransplant conditioning and infectious processes.

All tissue was fixed in 10% formalin and stained routinely with hematoxylin and eosin. In selected cases, pertinent blocks were also stained with elastica-van Gieson, Masson trichrome, and Perls' iron stains. To assure identification of any form of angiopathy throughout the body, slides of all available organs were reviewed.

In addition, sections of tissue from 3 cases were evaluated by transmission electron microscopy. Formalin-fixed tissue (2 cases) or tissue retrieved from the paraffin block (1 case) were placed in a solution of 2% paraformaldehyde, 2.5% glutaraldehyde, and 0.1 mol/L sodium cacodylate buffer. The samples were postfixed in 2% osmium tetroxide and then stained en bloc with uranyl acetate. After dehydration and infiltration, the tissue was embedded in epoxy resin. Thin sections were

---

From the Departments of Pathology and Hematology-Oncology, Children's National Medical Center, Washington, DC and the George Washington University Medical Center, Washington, DC. Accepted for publication October 1, 1998.

Presented in part at the Society for Pediatric Pathology Interim meeting in Minneapolis/St. Paul, September, 1997.

Address correspondence and reprint requests to Dena Selby, MD, Department of Pathology, Children's National Medical Center, 111 Michigan Avenue, NW, Washington, DC 20010.

Copyright © 1999 by W.B. Saunders Company  
0046-8177/99/3007-0002\$10.00/0

cut on an ultramicrotome, stained with lead citrate, and screened in an electron microscope.

Immunofluorescence studies were performed on frozen tissue for case 6. Tissue was embedded in OCT embedding medium, fixed in acetone, and subsequently incubated with fluoresceinated antisera directed against immunoglobulin (Ig)G, IgM, IgA, C3, C1q and fibrinogen by standard methods. This was followed by multiple washes in phosphate-buffered saline before mounting and examination under a fluorescence microscope.

**REPORT OF 6 CASES**

Information on the 6 cases is included in Table 1. Cases 1, 2, and 3 showed vascular changes in the small intestine, and cases 4, 5, and 6 showed vascular changes in the lungs.

**Case 1**

An 8-year-old black girl underwent an allogeneic, 6/6 HLA-matched, related, non-T-cell-depleted BMT for acute myelocytic leukemia. She developed recurrent gastrointestinal (GI) obstruction secondary to focal circumferential stenosis of the small bowel, requiring surgical resection at posttransplant days 180, 202, and 418. Vessel changes were present in all resection specimens. Her course was complicated by acute graft-versus-

host disease (GVHD) of the skin and gut which evolved into chronic GVHD, hemorrhagic cystitis, and multiple bouts of sepsis. She died on transplant day 448 at 9 years of age secondary to a surgical complication after placement of a broviac catheter. Similar vessel changes were seen in the small intestine at the time of autopsy.

**Case 2**

An 8½-year-old white boy with acute lymphoblastic leukemia (ALL) underwent an allogeneic, haploidentical, T-cell-depleted BMT from his mother with full engraftment. His clinical course was complicated by hemorrhage colitis early after BMT, hepatic veno-occlusive disease, and cytomegalovirus (CMV) pneumonia. Adenovirus was cultured from stool specimens and *Candida albicans* was cultured from both Broviac ports. He developed shock and died on posttransplant day 68. A complete autopsy was performed. GVHD was not noted at the time of autopsy.

**Case 3**

A 12-year-old white boy with pre-B-cell acute lymphocytic leukemia underwent an allogeneic, related, 5/6 HLA-matched, T-cell-depleted BMT. Donor marrow grew *Bacillus* sp. Engraftment was documented but the patient continued to be severely pancytopenic requiring frequent blood and platelet transfusions. Posttransplant complications included acute GVHD

**TABLE 1.** Clinical and Pathological Data on 6 Patients With Vasculopathy After Bone Marrow Transplant

	Case 1	Case 2	Case 3	Case 4	Case 5	Case 6
Age*/race/sex	8 y; BF	8½ y; WM	12 y; WM	3 m; WF	504 days 912 days; WM	13 y; BM
Primary Diagnosis	AML	ALL	Pre-B ALL	SCIDS (Ommen's)	Chediak-Higashi	Aplastic anemia
No. Allogeneic BMT	1	1	1	2	2	1
HLA match	6/6	3/6	5/6	5/6	3/6	5/6
Related	Sibling	Maternal	Sibling	Maternal	Maternal	Unrelated
T-cell depletion	No	Yes	Yes	Yes	Yes	Yes
Preparative regimen	Busulphan, cyclophosphamide, adriamycin	Cyclophosphamide, thiotepa, TBI	Busulfan, cyclophosphamide, cytosine arabinoside, TBI	Cyclophosphamide, thiotepa	Cyclophosphamide, cytosine arabinoside, TBI	Cyclophosphamide, cytosine arabinoside, TBI
GVHD Prophylaxis	Cyclosporin, methotrexate, prednisone	Antithymocyte globulin, prednisone	Antithymocyte globulin, prednisone	Antithymocyte globulin, prednisone	Antithymocyte globulin, prednisone	Cyclosporine, prednisone, methotrexate
GVHD (site)	Skin Small intestine	No GVHD	Skin Small intestine Large intestine	Skin	Skin	No GVHD
No. days after BMT to vasculopathy	180, 202, 418	68	95	13	497	14
Vasculopathy (site)	Small intestine	Small intestine	Small intestine	Lung	Lung	Lung
No. days after BMT to death	448	68	95	13	497	69
Cause of death	Surgical complication	HVOD	ARDS	Pulmonary edema	ARDS; PCP	Multiorgan failure

Abbreviations: BF, black female; WM, white male; WF, white female; BM, black male; AML, acute myelocytic leukemia; ALL, acute lymphoblastic leukemia; pre-B ALL, pre-B-cell ALL; SCIDS, severe combined immunodeficiency syndrome; BMT, bone marrow transplant; HLA, human leukocyte antigen; GVHD, graft-versus-host disease; HVOD, hepatic veno-occlusive disease; ARDS, adult respiratory distress syndrome; PCP, *Pneumocystis carinii* pneumonia; TBI, total body irradiation.

\*Age at time of BMT.

and aspergillosis requiring a right upper lobectomy 1 month after transplant. The lung specimen showed aspergillus with no evidence of vasculopathy. The patient died on transplant day 95 at 12 years of age and a complete post mortem examination was performed.

#### Case 4

A 3-month-old white female infant with Omenn Syndrome, a variant of Severe Combined Immunodeficiency Syndrome (SCIDS) with eosinophilia, underwent haploidentical (5/6) BMT of maternal, T-cell-depleted bone marrow on day 111 of life. Her clinical course was complicated by GVHD of the skin and multiple bouts of sepsis. She died on posttransplant day 13 at 4 months of age after being found unresponsive in her hospital bed. A complete post mortem examination was performed.

#### Case 5

A white male infant with Chediak-Higashi syndrome received an allogeneic, maternal, 3/6 HLA-matched, T-cell-depleted BMT at 504 days of age, and repeat transplant at 912 days of age from the same donor. His clinical course was complicated by development of a lymphoproliferative disorder successfully treated with ganciclovir, alpha-interferon, and gamma Ig. He developed GVHD confirmed by skin biopsy and *Pneumocystis carinii* pneumonia (PCP). He died on day 497 after the second transplant at 3 years of age. The autopsy performed was limited to liver, lungs, and lymphoid tissue. He died with adult respiratory distress syndrome (ARDS), pulmonary hypertension, systemic hypertension, and bradycardia.

#### Case 6

A 13-year-old black boy with nephrotic syndrome and aplastic anemia received an allogeneic, 5/6 HLA-matched BMT, and underwent a left upper lobe biopsy on posttransplant day 14 for evaluation of interstitial infiltrates/ARDS. The patient died on posttransplant day 69. An autopsy was not performed.

## RESULTS

Clinical and laboratory parameters within 2 days of the surgical or autopsy date were evaluated to rule out HUS and TTP. Data were available in 4 out of the 6 cases. Platelet count ranged from 18,000/mm<sup>3</sup> to 92,000/mm<sup>3</sup>; peripheral smear showed anisocytosis with no evidence of microangiopathic hemolytic anemia; creatinine was 0.3 mg/dL to 1.3 mg/dL and BUN 9 mg/dL to 63 mg/dL. There was no evidence of hypertension and no evidence of mental status changes.

There was no uniform conditioning regimen, with treatment including antithymocyte antibody, cyclosporine, methotrexate, prednisone, busulphan, cyclophosphamide, adriamycin, thiotepa, cytosine-arabioside, each stated in some but not all patients. Four patients (cases 2, 3, 5, and 6) received total body irradiation, and

two (cases 1 and 4) did not. There was documented radiation colitis in patient no. 2.

Documented infectious agents included herpes in 2 cases, CMV in 3, hepatitis C in 1, aspergillus in 1, varicella in 1, and Epstein-Barr virus-mediated lymphoproliferative disorder in 1. All patients had a course of bacterial (variety of species) or *Candida* infection while immunosuppressed.

## Gross Pathological Findings by Organ System

Changes of vasculopathy were appreciated in the GI tract or lung only. None of the patients showed involvement of both organ systems; GI tract or lung involvement was mutually exclusively of the other organ system.

*GI Tract.* Vasculopathy was seen in vessels of the small intestine in 3 cases.

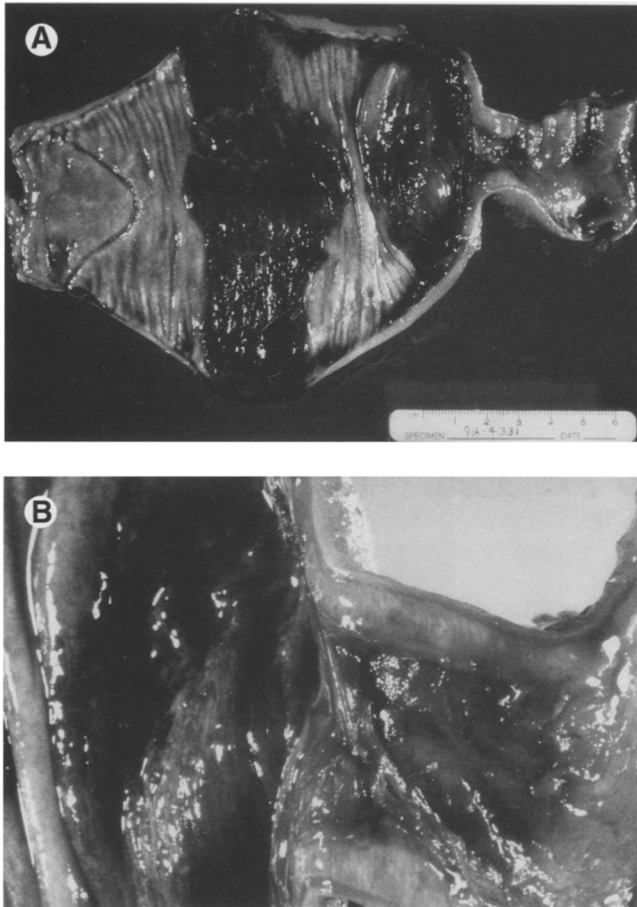
Case 1 had 3 separate surgical resections of obstructed small intestine. Bowel removed included a 2.8 cm length at the first surgery, a 23 cm length at the second surgery, and 2 segments, being 43 cm and 27 cm in length at the third surgery. All three showed similar gross findings. There was an abrupt dilatation of the proximal bowel. Sectioning revealed the lumen to be obstructed by a syncytial web composed of tan fibrous tissue. The mucosal surface in this area was eroded, granular, and brown, and the wall was thickened and edematous (Fig 1). Mucosa away from the involved site was intact and tan.

Case 2 showed congested jejunum and ileum with small scattered foci of mucosal hemorrhage, and a thickened mesentery studded with petechiae at the time of autopsy. Case 3 showed shaggy and hemorrhagic mucosa of the distal jejunum and ileum with focal petechial hemorrhage of the transverse and sigmoid colon.

*Lung.* Cases 4 and 5 showed hemorrhagic, solid lungs secondary to acute congestion and intraalveolar acute hemorrhage at the time of autopsy. A wedge biopsy of lung from case 6 had a solid, firm, red hemorrhagic cut surface.

## Microscopic Findings

Vessels in the GI and lung specimens showed similar histopathology. Small muscular arteries in the affected organ and some arteriolar sized vessels manifested the changes. The pathology included intimal hyperplasia, myxoid change, and intimal and medial fibrosis. The most prominent finding was concentric hyperplasia of the intima with some medial involvement (Fig 2). This finding was present in all the specimens, resulting in mild luminal compromise in case 6, and moderate-to-marked narrowing or luminal occlusion in all other cases. Interestingly, in case 1 the first 2 resection specimens had vessels with marked luminal compromise, where vessels from the third surgery showed only mild luminal compromise. There was prominent myxoid change of the vessel wall in three cases, predominantly intimal (case 1 in all 3 surgical resections, cases 5 and 6), and intimal edema in case 2.



**FIGURE 1.** (A) Surgical resection of obstructed bowel from case 1 shows abrupt narrowing and stenosis of the small intestine with dilatation of the proximal bowel. The lumen is filled with hemorrhagic contents. (B) A synctial web of fibrinous tissue occludes the lumen. There is ulceration of the mucosa in this region, and full-thickness edema of the intestinal wall.

A foamy change/vacuolization was present in the intima in 5 cases (cases 1, 2, 3, 4, and 6). Few red blood cell fragments were appreciated in the vessel wall in all cases. Foamy histiocytes were seen in the vessel wall in case 2, and perivascular in cases 4 and 5. Polymorphonuclear neutrophils were not seen.

All specimens showed intimal and medial fibrosis and minimal disruption of the elastic fibers. By Masson and elastica-van Gieson stains, the fibrosis was noted to be predominantly intimal. All three specimens from the GI tract had perivascular hemosiderin-laden macrophages suggestive of an earlier bleed (case 1 in all 3 surgical resections, case 2, and rare siderophages in case 3).

Small intestinal mucosa present over the involved vessels showed necrosis, ischemic damage, and granulation tissue response present in varying amounts in all 3 patients with GI vasculopathy. Two of these cases showed fibrin thrombi in vessels underlying the ulcerated mucosa (the second surgical resection of case 1, and case 3). There was no evidence of necrosis in the lung specimens, although diffuse alveolar damage (hyaline membranes) was present in cases 5 and 6.

These vascular changes were limited to the GI tract

or lung; vessels examined in other organ systems, when available for review, showed no abnormality. Larger vessels such as coronary arteries, renal arteries, aorta, and other elastic arteries showed no changes. There was no evidence of a TMA process in any of the other organs evaluated in the autopsy cases. Sections of the kidney were available for review in 3 of the 4 autopsy cases; there was no evidence of a TMA in these 3 cases.

Electron microscopic examination in cases 1, 4, and 6 revealed small muscular arteries with lucent expansion of the subendothelial space by hypodense fluffy material, fibrin and extravasated red blood cells (Fig 3).

Immunofluorescence staining of the lung in case 6 showed no staining of vessel walls with IgG, IgM, IgA, C3, C1q, or fibrinogen. There was diffuse staining of the alveolar capillary wall with fibrinogen, a finding not unexpected with the diffuse alveolar damage seen in the lung.

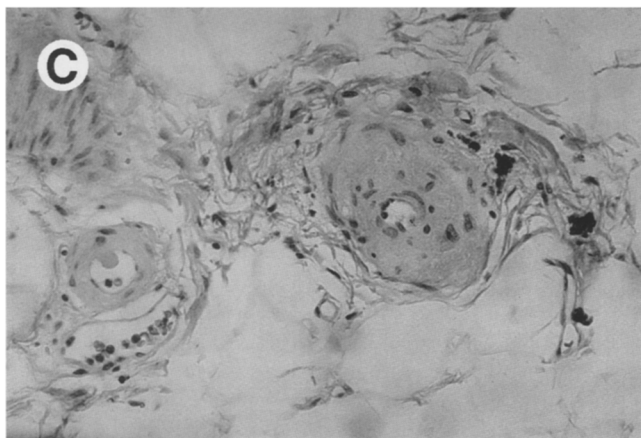
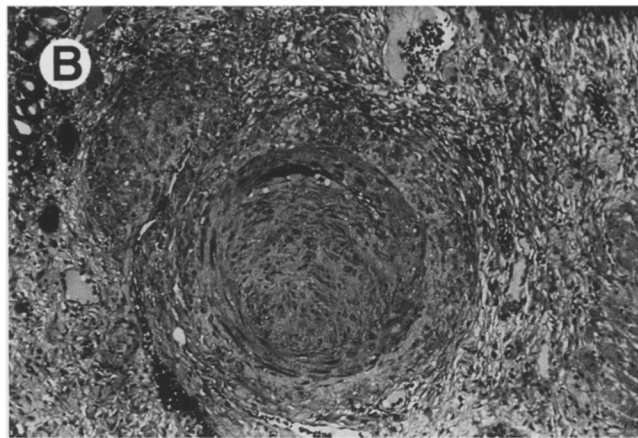
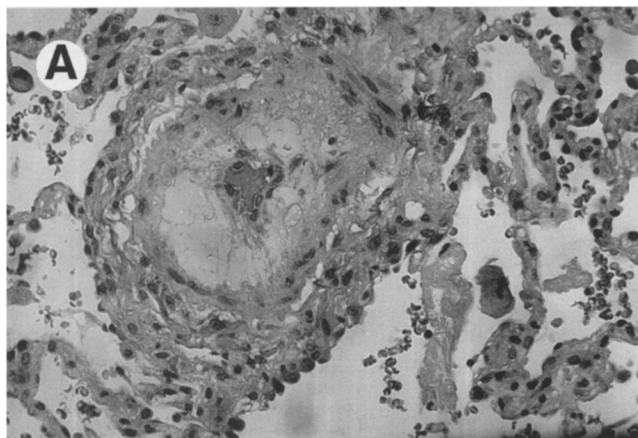
## DISCUSSION

The cases presented describe a distinctive vasculopathy seen in the lungs and GI tract of pediatric patients after BMT.

Although a post-BMT TMA is well described in the literature, this vasculopathy differs TMA (such as thrombotic thrombocytopenic purpura and hemolytic-uremic syndrome) for the following reasons: (1) the size of the vessel involved; in these cases, the majority of the vessels were small muscular arteries with some arteriolar involvement and in TMA the vessels are small; (2) no evidence of thrombosis in our cases, except focally in 2 cases, in which the thrombosis was near an ulceration site; (3) no evidence of renal disease in our cases at the time of pathological evaluation, evaluated by blood urea nitrogen and creatinine levels as well as histological review of the kidneys in 3 of the cases; and (4) no evidence of mental status changes. The possible causative agents accounting for TMA in patients after BMT may also play a role in the formation of the vasculopathy we describe, either individually or via negative synergy of several therapeutic modalities. The findings in the literature can be summarized as follows.

*Human Leukocyte Antigen.* An HLA-related disparity is an unlikely sole causative origin for this post-BMT vasculopathy. In a study by Byrnes and Hussain,<sup>1</sup> 32 out of 96 patients reported to have thrombotic microangiopathies such as TTP and HUS were status post an autologous bone marrow transplant. However, Silva et al<sup>2</sup> reported a 9-fold greater risk for development of HUS or TTP from allogeneic BMT than that of autologous BMT in patients treated with preparative regimens of cyclophosphamide, etoposide, and total body irradiation (TBI) (6.3% of 112 versus 0.7% of 146).

With increasing HLA disparity, there are increased requirements for use of immunosuppressants such as cyclosporine (CsA) as prophylaxis for graft rejection and GVHD. Cyclosporine has a number of sequelae which predispose to development of symptoms characteristic of TMAs.



**FIGURE 2.** (A) Small muscular arteries show intimal hyperplasia and myxoid change of the vessel wall (lung, case 3, original magnification  $\times 312$ ). (B) This vessel shows intimal fibrosis with almost complete occlusion of the lumen (intestine, case 1, original magnification  $\times 312$ ). (C) One arteriole vessel shows intimal hyperplasia and perivascular hemosiderin-laden macrophages (to right of vessel) suggestive of an earlier bleed (intestine, case 1, original magnification  $\times 312$ ).

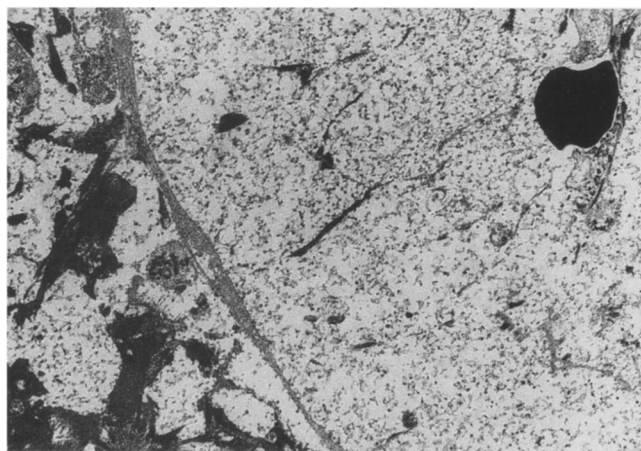
*Cyclosporine.* CsA is a cyclic peptide derived from a soil fungus and used as a systemic immunosuppressant. Although its exact mechanism of action is unknown, CsA is believed to block the action of nuclear transcription factors to inhibit cytokine transcription in T-lymphocytes and thus suppress production of interleukin-2 (IL-2), IL-4, interferon-gamma, and IL-2 receptors without affecting myelopoiesis.<sup>3</sup> IL-2 is a proliferative factor required for cytotoxic T-lymphocyte induction in

response to an alloantigenic challenge, a process of significance in both humoral and cellular immune responses. By down-regulating T-lymphocyte responses to alloantigenic challenges, CsA reduces acute graft rejection when administered before transplantation and is an effective posttransplantation prophylactic for GVHD in which the transplanted immunocompetent T-lymphocytes initiate a response against the immunologically challenged host.

The emergence of CsA revolutionized the efficacy of solid organ and bone marrow transplantation. When introduced for acute GVHD prophylaxis, several transplant centers reported benefits on survival rates.<sup>4</sup> However, the introduction of CsA was followed by a significant increase in the incidence of vascular and renal side effects in BMT and solid organ transplant recipients.<sup>5,6</sup>

There is an association of biochemical and morphological changes representative of generalized endothelial damage in allogeneic BMT patients receiving CsA<sup>4</sup> and the well-developed association between posttransplant patients and TMAs such as HUS and TTP.<sup>7</sup> Thrombotic microangiopathy may occur in up to 6% of patients after BMT.<sup>8</sup> CsA related TMA may involve several factors. CsA inhibits prostaglandin I<sub>2</sub> (prostacyclin), a potent endogenous vasodilator and inhibitor of platelet aggregation, production by cultured endothelial cells<sup>9</sup> while increasing the release of the thrombogenic eicosanoid thromboxane A<sub>2</sub> by platelets.<sup>10</sup>

CsA also increases plasma vWF levels, which have



**FIGURE 3.** Ultrastructural findings include small muscular arteries with lucent expansion of the subendothelial space showing hypodense fluffy material and fibrin. A single red blood cell is present in the narrowed lumen (original magnification  $\times 2,950$ ).

been used as an index of endothelial cell perturbation or injury, and CsA enhances platelet aggregation.<sup>11,12</sup> The vWF protein plays an important role in primary hemostasis because it is required for platelet adhesion to subendothelial collagen.<sup>13</sup> Together, these effects may precipitate TMA, however, it is unlikely that they are the sole causative agents because a few cases of primary TTP are reported to have resolved after institution of CsA as treatment.<sup>14,15</sup> In addition, TMAs have been observed post-BMT in patients not on CsA<sup>16,17</sup> and alterations in prostacyclin and thromboxane formation have also been attributed to TBI, another major component of the BMT regimen.

In a study by Holler et al,<sup>3</sup> 49 of 66 patients who underwent allogeneic BMT and received CsA for GVHD prophylaxis, presented with evidence of TMA. However, this was not observed in any of the 11 patients receiving methotrexate for GVHD prophylaxis. Ten of these 49 patients receiving CsA suffered from severe microangiopathy equivalent to TTP and 7 died as a result.

*Endothelin.* CsA has been shown in cultured human endothelial cells to induce synthesis of endothelin (ET),<sup>18</sup> a potent endothelium-derived 21-residue vasoconstrictor peptide that shows regional homologies to a group of neurotoxins which implies a role of ET as modulator of voltage-dependent ion channels.<sup>19</sup> Endothelins are also produced by macrophages<sup>20</sup> and they cause smooth muscle cell contraction (SMC) in tissue culture by influx of extracellular calcium via a process inhibited by calcium channel antagonists.<sup>18</sup>

Calcium channel blockers have been used to reduce the extent of acute tubular necrosis and decreased renal function induced by CsA in allogeneic renal transplants.<sup>21</sup> ET also causes proliferation of vascular smooth muscle cells, fibroblasts, and mesangial cells as well as producing protracted hypertension on systemic administration in human and animal experimental models.<sup>19,22,23</sup> CsA has been shown to stimulate endothelial cell synthesis of ET that then causes SMC proliferation, an action inhibited by coinubation with a calcium channel antagonist or an ET-specific antibody.<sup>18</sup>

High doses of in vivo CsA administration to rats has been associated with increased ET release, development of renal dysfunction and systemic hypertension.<sup>24</sup> ET has been associated with chronic vascular rejection (CVR) in rat cardiac allograft models at site of subocclusive and occlusive intimal proliferation associated with CVR.<sup>23</sup> In solid organ transplants, oral administration of CsA causes increased levels of circulating ET which has been hypothesized to contribute to CsA-associated nephrotoxicity and hypertension, particularly during long-term immunosuppressive therapy.<sup>25</sup> This theory is supported by a number of studies, but contradicted by 1 examination of ET levels after orthotopic heart transplantation in 18 patients in which ET levels did not correlate with CsA levels, mean arterial pressure, or serum creatinine.<sup>26</sup>

Administration of CsA has been shown to stimulate upregulation of endothelin receptors.<sup>23,27</sup> In addition, elevated plasma ET levels have been shown in CsA-treated patients after BMT in correlation with CsA

concentrations<sup>23</sup> and changes in microvascular permeability have been radiologically identified in post-BMT patients on CsA.<sup>28</sup> Therefore, although post-BMT patients not treated with CsA have presented with TMA,<sup>7,16,17</sup> there is evidence to support the role of ET in the development of a posttransplant vasculopathy in patients on CsA.

*Total Body Irradiation.* TBI was 1 of the 2 most common prophylactic treatments in a 1996 analysis of 96 reported cases of HUS or TTP in patients after BMT, the other being the chemotherapeutic agent cyclophosphamide (91% of cases with available information).<sup>7</sup> ET cell degeneration, thrombus formation, and vasoconstriction are among the effects of irradiation on vascular tissue. Pediatric patients are particularly susceptible to the effects of TBI<sup>29</sup> and thus there is a high potential for ET damage which is of great concern with TBI and central to the development of any form of vasculopathy.

A number of the proposed mechanisms of TBI-induced vascular injury are similar to those involving CsA. Of great interest is the role of prostacyclin and thromboxane. A 1981 study by Allen et al,<sup>30</sup> found that in vitro prostacyclin production was significantly decreased in the umbilical artery after a single dose of 200 rad in a dose-response manner, whereas platelet thromboxane production was unaffected after doses of 200 to 2,000 rad. The effects, similar to those of CsA, could shift the endogenous ET production of prostacyclin and thromboxane to a more thrombogenic level and may therefore serve as important factors predisposing to TMA and other forms of vasculopathy.

Exposure to radiation induces vascular changes that include accumulation of fluid in vessel walls and perivascular tissues, degeneration, swelling and necrosis of endothelial cells, morphological alteration of the vascular intima, and vaso-occlusive thrombi formation.<sup>30</sup> These changes become more interesting with the discovery that irradiation of an animal model acts synergistically with high cholesterol diets to cause severe atheromatous lesions not produced by either factor by itself.<sup>31,32,33</sup> Decreased prostacyclin production may be the means by which this occurs. One of our patients had documented radiation-induced colitis; however, 2 of our patients did not receive TBI.

This vasculopathy possesses histological characteristics similar to accelerated-graft atherosclerosis in cardiac transplant patients, and chronic rejection of renal, lung, and liver allografts. However, it differs in that it does not appear to be antibody mediated as evidenced by the negative immunofluorescence studies performed on case 6, a lung biopsy performed 14 days posttransplant. It is possible that repeated clinical or subclinical rejection episodes result in repeated vascular trauma.<sup>34</sup> With patients after BMT, the findings may similarly be related not to rejection, but to GVHD. Five out of 6 of our patients received BMTs from living, related donors; only 1 of the 6 patients had a 6/6 match, thus it would seem reasonable to suggest an HLA mismatch-based origin etiology. Four of our cases had histologically documented GVHD. In renal and cardiac

transplantation, vessel changes predict the long-term survival of the transplanted organ.<sup>35</sup>

Complications related to the vasculopathy included localized gastrointestinal obstruction secondary to luminal stricturing (case 1) and possibly the pulmonary hypertension clinically documented in case 5. We suggest ischemia secondary to vascular changes resulted in the fibrin outpouring and luminal stricturing of the GI tract; the pathogenesis of the pulmonary hypertension in the lungs is more speculative at this time.

The 6 cases presented show a distinctive vasculopathy of small muscular arteries after BMT. Vessels of the lung or GI tract may be involved. Histological features differ from accelerated atherosclerosis seen in solid organ transplants, and from TMA described post-BMT. The origin, which is not clear at this time, is most likely multifactorial to include effects of irradiation, chemotherapy, cyclosporine treatment, and/or GVHD.

*Acknowledgment.* The authors thank Ruth Graybill for her secretarial assistance.

## REFERENCES

1. Yousem SA, Paradis IL, Damber JH, et al: Pulmonary arteriosclerosis in long-term human heart-lung transplant recipients. *Transplantation* 47:564-568, 1989
2. Nagano H, Tilney NL: Chronic allograft failure: The clinical problem. *Am J Med Sci* 313:305-309, 1997
3. Byrnes JJ, Hussein AM: Thrombotic microangiopathic syndromes after bone marrow transplantation. *Cancer Investigation* 14:151-157, 1996
4. Silva VA, Frei-Lahr D, Brown RA, et al: Plasma exchange and vincristine in the treatment of hemolytic uremic syndrome/thrombotic thrombocytopenic purpura associated with bone marrow transplantation. *J Clin Apheresis* 6:16-20, 1991
5. Gordon MY, Singer JW: The effects of cyclosporin A on colony-formation by human lymphoid and myeloid cells. *Nature* 279:433, 1979
6. Holler E, Kolb HJ, Hiller R, et al: Microangiopathy in patients on cyclosporine prophylaxis who developed acute graft-versus-host disease after HLA-identical bone marrow transplant. *Blood* 73:2018-2024, 1989
7. Atkinson K, Biggs JC, Hayes J, et al: Cyclosporin A-associated nephrotoxicity in the first 100 days after allogeneic bone marrow transplantation: Three distinct syndromes. *Br J Haematol* 54:59-67, 1983
8. Berkenboom G, Unger P, Goldman M, et al: Prevention of cyclosporin A-induced vascular toxicity by pentoxifylline. *J Cardiovasc Pharmacol* 18:761-768, 1991
9. Moake JL, Byrnes JJ: Thrombotic microangiopathies associated with drugs and bone marrow transplantation. *Hematology-Oncology Clin N Am* 10:485-497, 1996
10. Pettitt AR, Clark RE: Thrombotic microangiopathy following bone marrow transplantation. *Bone Marrow Transplant* 14:495-504, 1994
11. Brown Z, Neild GH: Cyclosporine inhibits prostacyclin production by cultured human endothelial cells. *Transplant Proc* 19:1178, 1987
12. Grace AA, Barradas MA, Mikhailidis DP, et al: Cyclosporine A enhances platelet aggregation. *Kidney Int* 32:889, 1987
13. Charbra D, Moake JL, Harris MA: Abnormalities of von Willebrand factor multimers in drug-associated thrombotic microangiopathies. *Am J Hematol* 42:268, 1993
14. Fishman SJ, Wyloni LJ, Glickman JD, et al: Cyclosporin A augments human platelet sensitivity to aggregating agents by increasing fibrinogen receptor availability. *J Surg Res* 51:93-98, 1991
15. Remuzzi G, Zoja C, Rossi EC: Prostacyclin in thrombotic microangiopathy. *Semin Hematol* 24:110-118, 1987
16. DaSilva K, Pasquale D, Tsan MF, et al: Cyclosporine A (CyA), an effective therapy for thrombotic thrombocytopenic purpura. *Blood* 82:411a, 1993
17. Gable PS, Smith WS, Millard FE: Cyclosporine in relapsed thrombotic thrombocytopenic purpura. *Blood* 82:604a, 1993
18. Marshall RJ, Sweny P: Haemolytic uraemic syndrome in recipients of bone marrow transplants not treated with cyclosporin A. *Histopathology* 10:953-962, 1986
19. Loomis LJ, Aronson AJ, Rudinsky R, et al: Hemolytic uremic syndrome following bone marrow transplantation: A case report and review of the literature. *Am J Kidney Dis* 14:324, 1989
20. Bunchman TE, Brookshire CA: Cyclosporine-induced synthesis of endothelin by cultured human endothelial cells. *J Clin Invest* 88:310-314, 1991
21. Yanagisawa M, Kurihara H, Kimura S, et al: A novel potent vasoconstrictor peptide produced by vascular endothelial cells. *Nature* 332:411-415, 1988
22. Ehrenreich H, Anderson RW, Fox CH, et al: Endothelins, peptides with potent vasoactive properties, are produced by human macrophages. *J Exp Med* 172:1741, 1990
23. Sobh MA, Shehab El-Din AB, Moustafa FE, et al: A prospective randomized study of the protective effect of verapamil on ischemic renal injury in renal allotransplants. *Transplant Proc* 21:1230-1232, 1989
24. Forbes RDC, Cernacek P, Zheng S, et al: Increased endothelin expression in a rat allograft model of chronic vascular rejection. *Transplantation* 61:791-797, 1996
25. Haug C, Duell T, Lenich A, et al: Elevated plasma endothelin concentrations in cyclosporine-treated patients after bone marrow transplantation. *Bone Marrow Transplant* 16:191-194, 1995
26. Kon V, Sugiura M, Inagami T, et al: Role of endothelin in cyclosporine-induced glomerular dysfunction. *Kidney Int* 37:1487, 1990
27. Grieff M, Loertscher R, Al Shohaib S, et al: Cyclosporine-induced elevation in circulating endothelin-1 in patients with solid-organ transplants. *Transplantation* 56:880-884, 1993
28. Dorent R, Cacoub P, Carayon A, et al: Endothelin levels after orthotopic heart transplantation. *Transplant Proc* 26:250, 1994
29. Nambi P, Pullen M, Contino LC, et al: Upregulation of renal endothelin receptors in rats with cyclosporine A-induced nephrotoxicity. *Eur J Pharmacol* 187:113-116, 1990
30. Peters AM, Vassilarou DS, Hows JM, et al: Bone marrow transplantation: Effects of conditioning and cyclosporin prophylaxis on microvascular permeability to a small solute (Technetium-99 m diethylene triamine penta-acetic acid). *Eur J Nuclear Med* 18:199-202, 1991
31. Guinan EC, Tarbell NJ, Niemeyer CM, et al: Intravascular hemolysis and renal insufficiency after bone marrow transplantation. *Blood* 72:451-455, 1988
32. Allen JB, Sagerman RH, Stuart MJ: Irradiation decreases vascular prostacyclin formation with no concomitant effect on platelet thromboxane production. *Lancet* 2:1193-1196, 1981
33. Cohn KE, Stewart JR, Fajardo F, et al: Heart disease following radiation. *Medicine* 46:281-298, 1967
34. Dollinger MR, Lavine DM, Foye LV: Myocardial infarction due to post-irradiation fibrosis of the coronary arteries. *JAMA* 195:176-179, 1966
35. McReynolds RA, Gold GL, Roberts WC: Coronary heart disease after mediastinal irradiation for Hodgkin's disease. *Am J Med* 60:39-45, 1976