

New Approaches to Diagnosis and Arthroscopic Management of Partial-Thickness Cuff Tears

J.R. Rudzki, MD*, Benjamin Shaffer, MD

KEYWORDS

- Partial-thickness • Rotator cuff
- Overhead athlete • Diagnosis • Treatment

Partial-thickness cuff tears (PTCTs) are increasingly recognized as a source of pain and athletic impairment, especially in overhead athletes.^{1,2} Improvements in diagnostic imaging have enhanced the ability to detect and quantify partial cuff disease, and arthroscopic advances have led to novel techniques by which partial cuff tears can be repaired.²⁻⁶ Despite increasing recognition and improved understanding of this condition, the natural history, clinical evaluation, and management of partial tears remain elusive. This is because of the disparity between the extent of partial cuff tearing and the wide variability in clinical impairment and the frequent overlay of concomitant labral and subacromial pathology.

When should operating on an athlete with a partial cuff tear be considered? What percentage of cuff tear justifies repair rather than debridement? Does this threshold vary according to the athlete or sport? And if the partial tear is repaired, what can be expected in terms of return to activity, particularly in a high-level thrower? The purpose of this manuscript is to provide an overview of partial cuff tears and their evaluation and management.

BACKGROUND

Partial cuff tears have been recognized since they were first described in 1934 by Codman,⁷ who estimated their incidence to be likely twice that of full-thickness tears. The actual prevalence of partial-thickness rotator cuff tears, however, remains

Washington Orthopaedics and Sports Medicine, 2021 K Street, NW #400, Washington, DC 20006, USA

* Corresponding author.

E-mail address: dr.rudzki@wosm.com (J.R. Rudzki).

Clin Sports Med 27 (2008) 691–717

doi:10.1016/j.csm.2008.06.004

sportsmed.theclinics.com

0278-5919/08/\$ – see front matter. Crown Copyright © 2008 Elsevier Inc. All rights reserved.

somewhat unclear because of the variable methods by which tears have been assessed. Most data are derived from cadaveric and imaging studies of nonathletes. MRI studies in asymptomatic shoulders have found a variable percentage of partial-thickness tears, most of which occur within the supraspinatus tendon.^{1,8,9} In one review of 306 cadaveric shoulders, 32% had partial-thickness tears of the supraspinatus tendon.¹⁰ Intratendinous tears have been particularly common in comparison with articular- or bursal-sided tears. In a study of 249 cadaver shoulders, Yamanaka and Fukuda¹¹ found a 13% incidence of partial-thickness tears of which 55% were intratendinous, 27% were articular-sided, and 18% were bursal-sided.

In throwers, pathology within the cuff is especially common, particularly undersurface tears of the supraspinatus and infraspinatus. In a population of young athletes, Payne and colleagues¹² reported that articular-sided tears comprised 91% of all partial-thickness tears. Connor and colleagues,¹ in a study of 20 throwers, reported partial- or full-thickness cuff tears in 8 of 20 (40%) dominant shoulders, compared with none in nondominant shoulders. Because many athletes are never imaged, the true prevalence of PTCTs is probably higher than that reported.

ETIOLOGY OF PARTIAL CUFF TEARS

Partial cuff tears can occur on the bursal side, articular side, or within the tendon. The etiology of partial cuff tears is multifactorial,^{4,13,14} with clinical and basic science research suggesting that underlying mechanisms can be broadly categorized as either intrinsic or extrinsic to the rotator cuff tendons.^{13–16} Intrinsic factors are those that are inherent to the tissue, such as age-related degenerative tearing resulting from vascular and metabolic changes¹⁷ and internal shear stresses.^{10,18} Extrinsic factors include subacromial impingement, internal impingement, and stresses from repetitive overhead activities.

Intrinsic Factors

Age-related degenerative changes, more common in older athletes, include decreased cellularity, fascicular thinning and disruption, accumulation of granulation tissue, and dystrophic calcification.^{4,14} The hypovascular zone at the articular surface of the rotator cuff lateral to the so-called “rotator cable”^{19–22} is also accentuated with aging and likely contributes to the pathogenesis of partial-thickness tears.^{4,14,15,22} In addition, the bursal surface has more prevalent vessels with larger arterioles,^{19–21,23} and this more prominent blood supply has been suggested to play a role in the healing potential of bursal-sided tears. Intrinsic changes in the cuff vascularity and age-related degenerative changes may be responsible for articular-surface tears in patients older than 40 years without other clear mechanisms. This concept is further supported by clinical and cadaveric studies that have shown an increasing prevalence of partial-thickness rotator cuff tears with age and a histologic correlation noted between patterns of degenerative changes and areas of relative decreased vascularity.^{10,13,20,24,25}

Extrinsic Factors

Extrinsic factors include classic subacromial impingement as described by Neer,²⁶ shoulder instability,²⁷ traumatic injury, repetitive microtrauma, and internal impingement. Internal impingement most commonly occurs in overhead athletes, with the shoulder in abduction and external rotation (**Fig. 1**) and this contact may be pathologic or physiologic.^{25,28,29} Several potential factors may contribute to the development of pathologic internal impingement, including repetitive microtrauma and intratendinous strain during eccentric contraction of the rotator cuff in the deceleration phase of throwing. Other factors include subtle anterior instability through attenuation of the

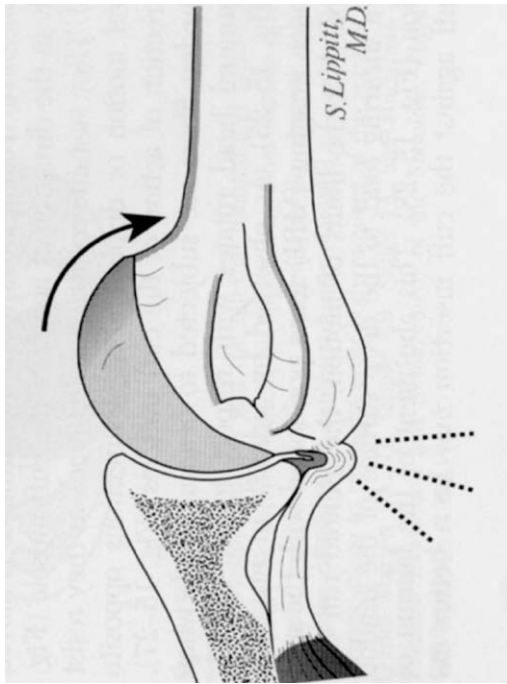


Fig. 1. Internal impingement occurs when the arm is placed in the throwing position of abduction and external rotation. In this position the posterior cuff impinges on the posterosuperior glenoid and rim. (From Mithoefer K, Fealy S, Altchek DW. Arthroscopic treatment of internal impingement of the shoulder. *Tech Shoulder Elbow Surg* 2004;5:66–75; with permission.)

anterior band of the inferior glenohumeral ligament, posterior capsular contracture, decreased humeral retroversion, tension overload, poor throwing mechanics, and scapular muscle imbalance.^{27,30–32} In overhead athletes, internal impingement is also currently considered a key factor in the pathogenesis of articular-surface partial-thickness tears.^{31,32}

Bursal-Sided Tears

Bursal-sided tears, common in middle- and older-aged athletes, have long been recognized and associated with subacromial impingement, whose classic extrinsic theory of rotator cuff pathophysiology was popularized in 1972 by Neer.²⁶ They can occur primarily or secondarily in association with intra-articular pathology.

Articular-Sided Tears

Articular-sided tears are more the purview of younger and overhead athletes and are thought to be 2 to 3 times more common than bursal-sided tears.^{33–36} Rotator cuff pathology in this population typically represents partial-thickness tears of the articular side of the posterior supraspinatus and anterior infraspinatus.^{1,2,37} Snyder and colleagues,³⁸ in 1991, described these articular tears as partial articular-sided tendon avulsion (“PASTA”) lesions. The current proposed mechanisms of failure include repetitive microtrauma, tension overload, higher modulus of elasticity, subtle anterior instability, internal rotation deficit, internal impingement, and adaptive changes of the

humerus and glenoid.^{2,25,27,37,39-41} Nakajima and colleagues⁴² reported the ultimate stress to failure of the articular surface of the cuff to be approximately half that of the bursal surface, with thinner, less uniformly arranged collagen bundles. A recent biomechanical cadaveric study by Mazzocca and colleagues¹⁸ found that articular-sided tendon strain increases consistently across the supraspinatus tendon with increased size of partial tears and that repair can return strain close to the intact state.

The cuff has been shown to have differential anatomy, including vascularity and tendon composition, with less distinct and more randomly oriented collagen bundles (Fig. 2).^{22,23,26,40,43} Several studies have also demonstrated that the articular side of the rotator cuff is hypovascular when compared with the more prominent blood supply to the bursal surface.²² The relative frequency of articular-sided versus bursal-sided partial-thickness^{13,22,37,40} tears may potentially be related to this difference in vascularity.

Intratendinous Tears

Recent literature has emphasized a growing interest in the role of intratendinous strain in the pathogenesis of rotator cuff pathology.^{17,18,29,43,44} Intratendinous strain as a causative mechanism of partial-thickness rotator cuff tears is especially relevant in overhead athletes, whose rotator cuffs are placed under repetitive strain, with powerful eccentric forces acting on the tendon during deceleration in the throwing motion.²

A cadaveric biomechanical study by Bey and colleagues⁴² found that partial articular-surface tears developed increased intratendinous strain at more than 15° of shoulder abduction. Another cadaveric study by Reilly and colleagues⁴⁴ demonstrated that intratendinous defects resulted in elevated strain patterns within the tendon, which are increased on the articular surface with shoulder abduction to 120°. These same investigators noted tear propagation from the articular to the bursal surface and concluded that load sharing through the supraspinatus tendon was altered by an intratendinous tear. A corresponding increase in articular-surface strain sufficient to compromise cuff integrity was also noted at and above 90° of abduction.

Walch and colleagues²⁹ described intratendinous extension of articular-surface tears into the middle layers of the infraspinatus tendon in throwing athletes with

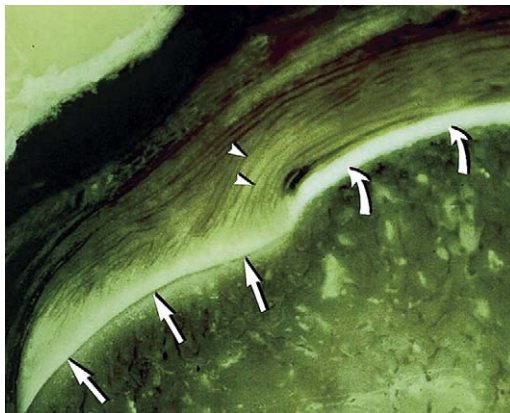


Fig. 2. Tendinous insertion of the supraspinatus of the rotator cuff. Note the thinner, less-uniform collagen bundles of the articular side (*arrowheads*). (From Stetson WB, Phillips T, Deutsch A. The use of magnetic resonance arthrography to detect partial-thickness rotator cuff tears. *J Bone Joint Surg Am* 2005;87:81-8; with permission.)

internal impingement. In a group of 8 cuff tears in 14 throwers, he observed that “some tears extend into the depth of the tendon, dissecting into 2 layers.” Nakajima and colleagues⁴² has further reinforced the creation of shear stresses and intratendinous tears in overhead athletes as a consequence of the 5-layered architecture of the cuff, which allows tangentially and perpendicularly opposed vector forces to occur within the tendon. Yamanaka and Fukuda¹¹ and Conway² separately expanded on this development by drawing additional attention to the commonly occurring intratendinous extension of these lesions particularly in overhead-throwing athletes. Conway proposed the term PAINT lesion to describe partial-thickness articular-surface tears with intratendinous extension (Fig. 3). These lesions are thought to occur because of internal impingement, with shear stresses generated as the cuff, particularly the infraspinatus, is draped over the posterior-superior glenoid during late cocking and early acceleration.

ANATOMY

Anatomic restoration of the normal cuff’s footprint depends on understanding normal cuff anatomy. Near its insertion, the cuff is composed of 2 components, the rotator cable, a cable-like thickening suspending from the cuff from just posterior to the biceps tendon to the infraspinatus tendon, and the rotator crescent, cuff tissue that bridges from the cable to the tuberosity. Nearly all articular-sided cuff tears are limited to the rotator crescent area of the supraspinatus, extending into the infraspinatus (Fig. 4).

Several studies have examined the anatomic insertion of the cuff, which is important for surgical efforts to anatomically restore the footprint and to facilitate estimating tear extent based on known cuff dimensions. In a study of the cuff’s anatomic insertions, Dugas and colleagues⁴⁵ reported a mean minimum transverse dimension of approximately 14.7 mm, occurring in the middle portion of the supraspinatus. The distance from the articular margin to the most medial cuff fibers was less than 1 mm along the anteriormost 2.1 cm of the cuff insertion. This distance progressively increased posteriorly in the region of the infraspinatus to a mean distance of 13.9 mm at the most inferior aspect of the teres minor insertion. This information serves to highlight the appropriate site for tendon advancement and repair. Nonanatomic advance of the articular tear medial to the normal insertion site (1 mm from articular margin for

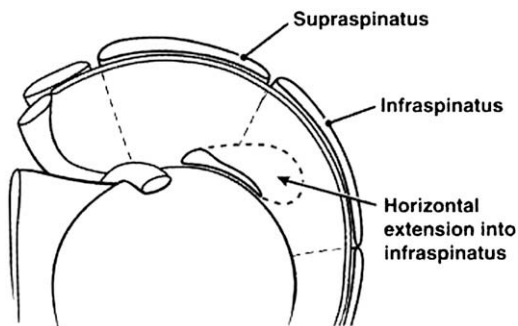


Fig. 3. The most common articular-sided tears in throwers occur at the supraspinatus/infraspinatus junction. Intratendinous extension into the infraspinatus is a common finding in these shoulders. (From Conway JE. Arthroscopic repair of partial-thickness rotator cuff tears and SLAP lesions in professional ball players. *Orthop Clin North Am* 2001;32:443–56; with permission.)

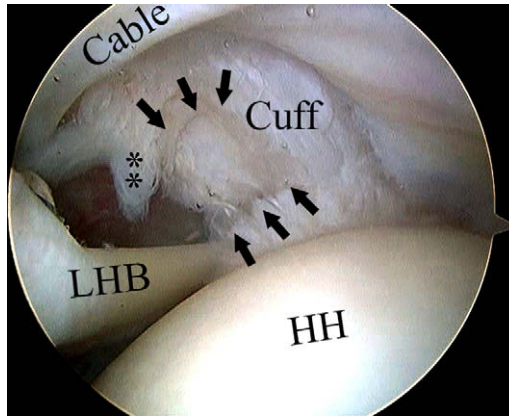


Fig. 4. Undersurface cuff tear in right shoulder, viewing with scope from posterior portal. Note the rotator cuff cable, with the tear occurring in the crescent portion of the cuff. Arrow shows margins of the cuff tear with small flap tear (**). HH, humeral head; LHB, long head of biceps.

the supraspinatus, 3 mm and increasing as one goes posteriorly for the infraspinatus tendon) risks overconstraint of the throwing shoulder.

EVALUATION

Evaluation of the athlete's shoulder begins with a careful history, including symptom onset, character, location, referral, and phase of the activity in which the symptoms occur (eg, does it occur in the late cocking/early acceleration during the throw, overhead in the tennis serve, or the pull-through phase of the swim stroke). The nature of onset is important because most overhead-throwing athletes do not have a discrete event, but instead have symptoms that evolve because of overuse. In the younger population, acute injury more likely suggests a labral injury. In the older population, cuff tears are more likely. Partial- and full-thickness cuff tears in athletes can be surprisingly variable in their presentation, ranging from mild discomfort and decreased throwing velocity to chronic aching pain and inability to serve overhead or throw.

It is important to discern whether the athlete has symptoms, such as mechanical clicking, popping, catching, or a sense of instability or dead-arm. Response to activity modification, therapy, medication, or injections should be determined. A history of orthopedic problems should be elicited because they may contribute to or influence treatment.

PHYSICAL EXAMINATION

Physical examination for partial cuff tears can be challenging because the findings are non-specific and often overlap with other coexistent pathology. Important examination highlights include inspection, assessment of motion and strength, and performance in provocative tests. Inspect for muscle atrophy and scapular dyskinesis during elevation and against resistance. Core strength and control can be assessed using the single leg squat described by Burkhart and colleagues and Kibler and colleagues.^{46,47} Assess active and passive range of motion (ROM), recognizing that such assessment is most accurate when stabilizing the scapula to determine true glenohumeral motion. Pitchers commonly demonstrate increased external and decreased internal rotation on the injured side

compared with the opposite shoulder. Palpation may reveal tenderness over the supraspinatus insertion, the posterior glenohumeral joint capsule, biceps tendon, or the acromioclavicular (AC) joint. Cuff strength testing should include assessment of the supraspinatus, infraspinatus, and subscapularis tendons. Kibler and colleagues⁴⁷ emphasized that supraspinatus strength testing requires scapula stabilization for true assessment.

Several physical examination tests have been described to assist in diagnosis of rotator cuff pathology. Impingement signs of Neer and Hawkins have long been advocated but are probably not specific for subacromial impingement.^{26,37,48,49} Several recent tests have been described to detect internal impingement, including the impingement sign,⁵⁰ modified relocation,⁵¹ and the internal rotation resistance.⁵² Unfortunately, a few of these tests have been independently evaluated, and their true sensitivity and accuracy are unknown. In addition, the reliability of these maneuvers may differ among examiners.^{53,54} In a review of special tests to evaluate rotator cuff pathology, Tennent and colleagues⁵³ noted “Many were originally described without recourse to evidence-based medicine, but have now become part of the standard orthopaedic criteria” and that “Often these tests are of little help in confirming a diagnosis.”

Instability testing requires the performance of translational, sulcus, and apprehension testing. The active compression test described by O’Brien and colleagues⁵⁵ may be useful to determine the presence of a superior labral anterior to posterior (SLAP) lesion. Focal tenderness over the AC joint with cross-body adduction may reflect AC joint pathology. Evaluation of the cervical spine and a thorough neurovascular examination of the upper extremity complete the examination.

IMAGING

Although plain radiographs are rarely helpful in the diagnosis of PTCTs, these radiographs are an essential part of evaluating patients with shoulder pain. Although nonspecific, enthesopathic changes at the greater tuberosity, including notching and cystic changes, have been associated with partial-thickness articular-surface tears in throwing athletes.⁵⁶ An outlet view is of value in determining acromial morphology, a prerequisite for potential surgical candidates.

The primary modalities for assessment of PTCTs are MRI and ultrasonography. Increased use and improved techniques of ultrasonography have led to its emergence as a useful tool in the assessment of rotator cuff pathology (**Fig. 5**).^{8,57} For the diagnosis of partial-thickness rotator cuff tears, Wiener and Seitz⁵⁸ reported a sensitivity of 94% and a specificity of 93%. Despite the benefits of ultrasound, including its ability to dynamically assess the cuff, patient tolerance, and cost, it is highly operator-dependent. Consequently, it has yet to gain more than regional foothold because of its dependence on those with expertise to perform and interpret the studies.

Currently, MRI remains the modality of choice for imaging athletes with suspected cuff pathology (**Fig. 6**). The use of standard MRI has been only moderately successful in the diagnosis of partial-thickness tears, with previous studies reporting sensitivity rates between 56% and 72% and specificity rates of 85% for tears confirmed with arthroscopy.⁵⁹ Gartsman and Milne¹⁶ reported a false-negative rate of 83% in a study of 12 arthroscopically verified articular-sided partial-thickness tears. Owing to these disappointing results, fat-suppression,⁶⁰ contrast MR arthrography (MRA),⁶¹ and positional variation have been introduced to improve diagnostic accuracy. Gadopentate contrast-MRA with coronal oblique fat-suppression sequences has been reported to have a sensitivity of 84%, a specificity of 96%, a positive predictive value of 93%, and an overall reported accuracy of 91%.⁶² Placing the shoulder in the throwing or abduction external rotation (ABER) position is of particular value in the throwing

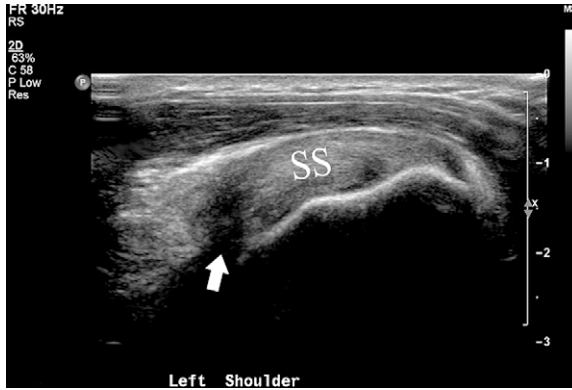

Fig. 5. Ultrasound image demonstrating an articular-side tear (*arrow*) at the medial footprint of the supraspinatus tendon insertion. SS, supraspinatus. (Courtesy of R. Adler, MD, New York, NY.)

athlete (**Fig. 7**). These sequences have improved the detection of labral and cuff tears. Lee and Lee⁶¹ demonstrated that at the time MRA was performed using a coronal oblique view, the sensitivity for articular and intratendinous rotator cuff tears was 21%. At the time ABER sequencing was performed, the sensitivity rose to 100%. Although current literature suggests that ultrasonography and MRI have similar sensitivity and specificity in the diagnosis of partial-thickness tears,⁸ another significant advantage of MRI is its ability to diagnose other pathology, such as labral tears.

TREATMENT

Treatment depends on many factors, including the athletes' symptoms, nature of onset, degree of impairment, response to treatment, timing with respect to season,

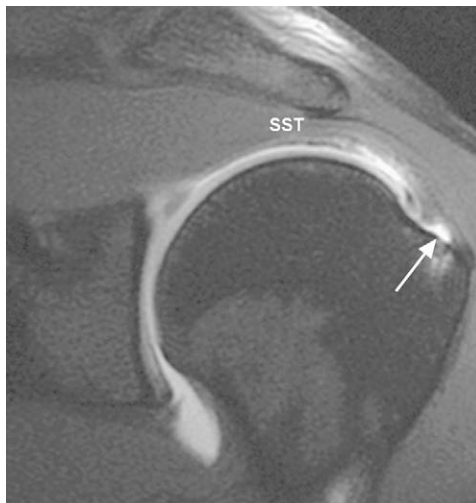


Fig. 6. This coronal fat-saturated T1 image demonstrates partial-thickness tearing at the undersurface of the supraspinatus tendon (*arrow*).

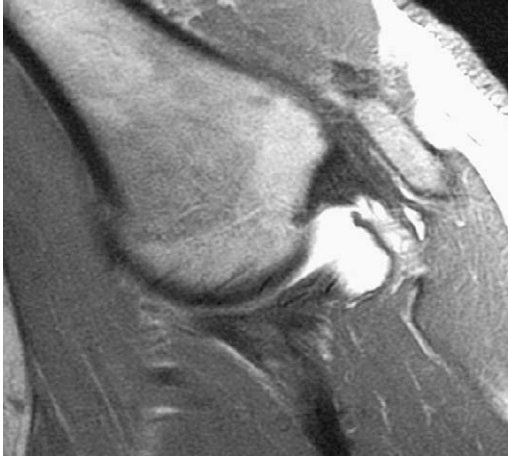


Fig. 7. This coronal MR arthrogram of the left shoulder has been obtained with the arm placed in the ABER position, permitting visualization of the undersurface and intratendinous tear at the supraspinatus/infraspinatus junction. (From Brockmeier SF, Dodson CC, Gamradt SC, et al. Arthroscopic intratendinous repair of the delaminated partial-thickness rotator cuff tear in overhead athletes. *Arthroscopy* 2007; epub ahead of print; with permission.)

and associated pathology. Treatment also depends on understanding the natural history and classification of partial rotator cuff tears.

NATURAL HISTORY

Several investigators have demonstrated that partial-thickness tears do not have inherent healing potential.^{63,64} For example, in a group of 40 patients with articular-sided partial cuff tears, arthrographic follow-up showed an 80% rate of progression; 51% enlarged, 29% went on to full thickness, 10% became smaller, and 10% went on to healing. Prognosis in their group was worse with increasing age, size, and absence of trauma.⁶³

However, some athletes have been the focus of natural history studies, so the authors know less about this group of patients. In a study of a 5-year follow-up of 8 throwers with PTCTs, none had any subjective symptoms or required evaluation or treatment for shoulder-related problems during the study period.¹ In throwers, articular-sided tears are believed to have a poor prognosis for several reasons: separation of tendon edges, poor vascularity of involved tissues, formation of a synovial covering within the intratendinous segment of the tear, and continued internal impingement with contact between the cuff and the glenoid rim while throwing.

CLASSIFICATION OF PARTIAL-THICKNESS ROTATOR CUFF TEARS

Classification is an important component for preoperative and intraoperative considerations. Determination of cuff tear location and extent influences treatment decision-making and permits comparison when evaluating treatment outcomes. The first classification of partial tears was included in Neer's⁴⁸ classification of the spectrum of cuff pathology. This classification presented cuff tendinopathy as a spectrum

extending from stage I (inflammation, hemorrhage, edema, and pain) through stage II (tendon fibrosis) to stage III (progressive tearing).

The current understanding of rotator cuff pathology has expanded substantially to include several mechanisms other than outlet impingement in the development of partial-thickness tears. Ellman's³³ classification of partial-thickness rotator cuff tears included descriptions based on tear depth (grade 1: <3 mm deep or 25%; grade 2: 3 to 6 mm deep or 50%; and grade 3: >6 mm deep or >50%) and tear area (in square millimeter). Snyder and colleagues³⁸ revised this classification system to include location (articular, bursal, or complete) and tear severity (0–4 scale, ranging from normal to more than 3 cm severe cuff injury).

NONOPERATIVE MANAGEMENT

Overhead athletes with partial-thickness tears are managed with a conservative course of treatment, including activity modification, oral nonsteroidal anti-inflammatory medication, and a tailored rehabilitation protocol to optimize ROM and cuff and scapular rotator strength. Individual athlete, sport, and season-specific considerations may influence subsequent steps. Additional treatment options include subacromial or intra-articular corticosteroid injections. Anterior capsular tightness is addressed by external rotation stretching with the shoulder adducted at the side to avoid placing the shoulder in a provocative position of impingement (60° to 120° of abduction). Posterior capsular contractures are addressed by stretching with the arm abducted and internally rotated (sleeper stretches).³⁰ Thermal modalities (eg, moist heat and ultrasound) may be used adjunctively, although data to support their use are limited. When pain decreases and rotator cuff strength and function improve, strengthening of the shoulder girdle and core abdominal and thoracic muscles is emphasized to restore normal scapulothoracic and trunk rotation mechanics. If not addressed, scapulothoracic dyskinesia increases the likelihood of extrinsic subacromial impingement of the rotator cuff.⁴⁶ Restoration of proper mechanics is facilitated by a progressive interval throwing or activity program with a sport- and position-specific focus.

OPERATIVE MANAGEMENT

Surgical intervention for PTCTs is considered in athletes unresponsive to nonoperative treatment. The duration of nonoperative treatment varies based on the presentation, physical and imaging findings, degree of impairment, and patient demands and expectations. The threshold for operative intervention is higher for throwers because of the prevalence of partial cuff tears, the frequent disparity between imaging findings and clinical symptoms, and the current unpredictable outcome if repair is performed.

Surgical alternatives for treating partial cuff tears include arthroscopic cuff debridement or repair, performed arthroscopically or open. Both approaches may also include subacromial decompression or labral debridement or repair, as necessary. Such decisions may be anticipated before surgery, but are usually determined at the time of arthroscopy and are influenced by factors such as the patient's age, tissue quality, estimated tear depth, presence of additional pathology, and surgeon experience. Generally, partial tears are considered for repair in more than 50% of the tendon thickness in non-overhead athletes. Some investigators have suggested an even lower threshold for considering repair. In a series of patients with and without workers' compensation injuries, Nicholson⁶⁵ concluded that 30% partial-thickness tendon involvement with persistent symptoms ought to be considered for repair.

However, the tear grade required to repair PTCTs in throwers is different. This population poses a difficult therapeutic challenge because the etiology and natural history of PTCTs in overhead athletes is unique. The high forces to which the cuff is subjected consequent to the exaggerated positional requirements of throwing threaten repair integrity and biomechanic preservation of the throwing motion. Therefore, the threshold for repair of throwers' PTCTs is considerably higher than that for nonthrowers and must approach 75% for repair consideration.

DEBRIDEMENT

Glenohumeral Joint

Arthroscopic debridement is an important component to remove unstable flaps and to permit assessment of tear depth and extent. A thorough diagnostic examination is first performed in the glenohumeral joint. Articular-sided cuff tears are addressed using a motorized shaver to remove pathologic tissue back to a healthy stable margin. Sometimes this requires debridement from the anterior and posterior portals. A non-aggressive blade shaving in one direction (rather than oscillating) seems to be less traumatic and leaves a smoother debrided surface (**Fig. 8**). A curved blade facilitates undersurface cuff debridement. When present (especially in throwers) intratendinous pathology is debrided to remove unhealthy tissue and to enhance a healing response in the delaminated layers. If an articular-sided tear has been debrided, a spinal needle is used to percutaneously pass a monofilament marking suture (#1 polydioxanone suture [PDS]) into the cuff defect before withdrawing the scope from the glenohumeral joint (**Fig. 9**). This procedure facilitates assessment of the cuff on the corresponding bursal side (**Fig. 10**). Any labral, subscapularis, biceps, or chondral pathology is addressed at this time.

Subacromial Space

The subacromial space is examined to assess the integrity of the bursal side of the cuff and evaluate for subacromial impingement. The bursa can be distended before this step (10 mL of 0.25% bupivacaine with epinephrine), because it facilitates the entrance of the scope and minimizes bleeding. A blunt obturator is used to "pop" into the space from the posterior glenohumeral scope portal. Successfully entering

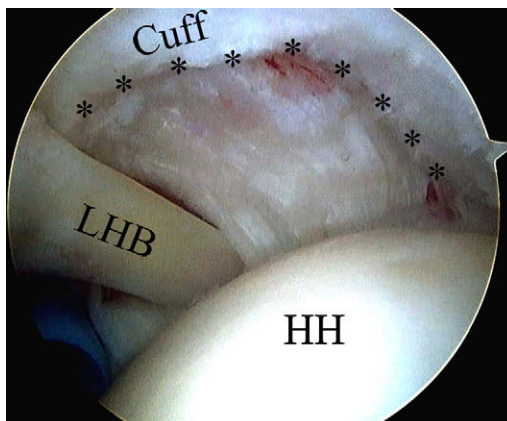


Fig. 8. Right shoulder viewed from posterior scope portal shows partial-thickness defect after debridement. *Cuff tear margin; HH, humeral head; LHB, long head of biceps.

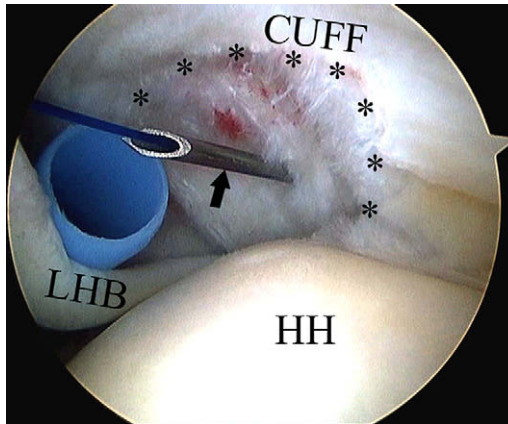


Fig. 9. Arthroscopic view of right shoulder from posterior portal shows passage of a monofilament marking suture by way of a spinal needle (arrow) into the central portion of the debrided articular cuff defect margin (*). HH, humeral head; LHB, long head biceps.

the bursa is advantageous because it permits clear visualization of the subacromial space and may preclude the need for any operative intervention. Inadvertent entrance into the prominent posterior subacromial bursal veil can mistakenly lead to the perception that there is bursal hypertrophy and subacromial impingement and lead to unnecessary bursectomy or subacromial decompression. Avoiding such unnecessary additional trauma or surgery is of particular value to athletes and their recovery timetable.

When a bursectomy is necessary, care should be taken to avoid inadvertently cutting the marking suture. Subacromial decompression may be warranted when there is evidence of impingement accompanied by preoperative assessment of acromial morphology. Subacromial decompression may also be of value to facilitate visualization and working space at the time of performing an arthroscopic cuff repair.

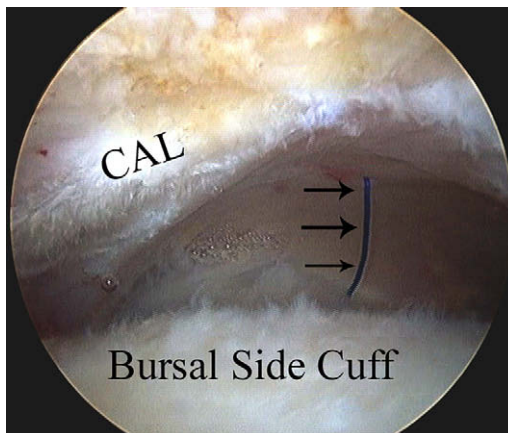


Fig. 10. Arthroscopic view of subacromial space of right shoulder from posterior portal, demonstrating corresponding percutaneously placed marking suture (arrows). CAL, coracoacromial ligament.

Debridement Results

The outcome after arthroscopic debridement has been well documented. In a study of the general population, Budoff and colleagues⁶⁶ evaluated 79 shoulders with partial-thickness tears treated with arthroscopic debridement at 25- to 93-month follow-up. A large percentage of these patients (77%) had associated labral pathology. The investigators reported good to excellent results in 89% of patients with less than 5 years of follow-up based on the University of California at Los Angeles (UCLA) shoulder rating scale. However, with longer follow-up, 5-year good and excellent results decreased to 81%.

The literature also contains reports of favorable results after debridement of partial-thickness rotator cuff tears and concomitant subacromial decompression. Snyder and colleagues³⁸ reported their results of a retrospective review of 31 mostly recreational athletes with partial-thickness tears treated with arthroscopic debridement and acromioplasty and reported 84% good-to-excellent results. Of the 31 patients in their study, 18 underwent acromioplasty, which had no significant difference in outcome. No throwing athletes were in this group. In a nonathletic population, Esch and colleagues⁶⁷ reported their results of arthroscopic subacromial decompression according to the degree of partial-thickness tear and noted that 76% of the patients with a partial-thickness tear demonstrated satisfactory scores on the UCLA shoulder rating scale, with improvements in pain, function, active forward flexion, and strength.

In a group of 32 nonathletes subjected to cuff debridement with or without acromioplasty, Weber⁶⁸ reported only fair results. At second look arthroscopy, he noted, "healing was never observed." Cordasco and colleagues⁶⁹ evaluated the clinical outcomes of arthroscopic debridement and acromioplasty in 162 patients (cohort not described with respect to activity level; presumed to be nonathletes) with normal or partial-thickness tears of the rotator cuff. The investigators found no difference in outcome between those with partial-thickness tears less than 50% of tendon thickness and those without a tear. However, they noted an increased failure rate in patients with grade 2B (bursal-sided tears affecting less than 50% of tendon thickness). As a result, they recommended repair in combination with acromioplasty for this subgroup of bursal-sided tears.

The outcome in throwers is less predictable. Few series have examined the outcomes after debridement in elite overhead athletes. Andrews and colleagues⁷⁰ reported 85% good-to-excellent results with arthroscopic debridement of partial-thickness tears in 34 young overhead athletes at a mean 13-month follow-up. All patients in the study had associated labral pathology and 25% had abnormalities of the long head of the biceps tendon.

Payne and colleagues¹² evaluated 43 athletes younger than 40 years with partial-thickness tears treated with arthroscopic debridement and subacromial decompression. Almost three fourths of their cohort included overhead athletes (baseball, softball, swimming, and tennis). They reported an 86% satisfactory outcome with acute traumatic injuries, versus a 64% rate of return to preinjury athletic activity. Those with insidious onset of pain from a partial-thickness tear were less successful, with only a 66% satisfactory outcome and 45% rate of return to preinjury athletic activity.

In an unpublished study by Kim,⁷¹ 109 patients were evaluated at 49 months follow-up after either debridement for Ellman I and II or conversion to full-thickness tear, and repair for Ellman III PTCTs. Patients were divided into 3 groups: (1) throwing athletes (N = 49; average age, 27 years), (2) non-throwing athletes (N = 32; average age, 31 years), and (3) nonathletes (N = 28; average age, 56 years). Those undergoing debridement had the highest incidence of unsatisfactory results. Eleven of the

19 with grade II partial tears failed arthroscopic debridement. Of the 10 with grade III partial tears repaired arthroscopically, 7 had a satisfactory American Shoulder and Elbow Surgeons (ASES) self-report score. Return to activity was lowest in group 1 (73%). Based on this, they concluded that arthroscopic debridement alone could not be justified in throwing athletes with more than Ellman grade 2 tears and advocated arthroscopic repair in these high-demand patients. They also observed that return to activity was inferior in throwing athletes versus nonthrowers or nonsports participants.

REPAIR

Poor outcome with debridement, concern about tear progression, and advances in arthroscopic repair techniques have led to the growing perception that partial cuff tears ought to be repaired more frequently. Historically, 50% of the medial-lateral tendon width has been used as a guide for considering repair. Yet this perspective has little scientific basis. In a retrospective study, Weber⁶⁸ reviewed the outcomes after arthroscopic debridement and acromioplasty versus acromioplasty and mini-open repair at 2- to 7-year follow-up. In the arthroscopic debridement group, there were 14 good and no excellent results, compared with the repair group, which had 28 good and 3 excellent results. Therefore, Weber recommended repair of partial-thickness tears more than 50% of the tendon thickness.

In addition to the uncertainty about what percentage tear deserves repair, there is no technique for accurately measuring tear percentage directly. Current strategies to assess tear extent rely on indirect techniques. The most common is to compare a known reference (such as a shaver blade with known dimensions) with the amount of exposed footprint. This estimate is then compared with the average cuff thickness, conventionally considered an average of 12 mm. However, Spencer and colleagues⁷² showed that when estimating the depth of PTCTs, interobserver agreement is poor (0.44).

Compounding measurement inaccuracy is that the standard reference by which partial cuff tears are compared is 12 mm. Yet, tendon thickness varies considerably. Six millimeters of exposed footprint may be less than or more than 50% the tendon footprint, depending on the individual patient. There is no current technique by which the individual's tendon dimensions are directly measured intraoperatively. Perhaps, each patient's footprint dimensions can be measured preoperatively using imaging studies.

Even if there is a reliable technique for measuring cuff tear involvement, other factors, such as tear configuration, influence repair decision-making. For example, some patients have unstable partial flap tears that respond to debridement alone, even if the tear approaches (or exceeds) 50%. Stable but deficient PTCTs may not do as well without repair. Concomitant pathology, such as labral injury or impingement, may also influence decision-making. Repair may be influenced by an athlete's age or sport position. For example, an older pitcher (older than 30 years) with a significant partial-thickness cuff tear is probably better served by debridement alone, compared with a younger pitcher or position player, in whom repair may be a reasonable consideration.

Advances in arthroscopic repair technology have probably lowered the threshold for repairing cuffs in nonthrowers, considering repair for PTCTs as low as 35%. Overhead athletes, however, have not shown uniformly good results with arthroscopic repair, so decision-making in this group is more tenuous, and the threshold for repair in throwers approaches 75%. This approach is somewhat empiric and has insufficient clinical or

biomechanical justification. Ultimately, the intraoperative decision-making process not only takes into account more than merely the estimated PTCT dimensions, but also considers associated pathology, age, tissue quality, sport, position, and demands/expectations.

Repair Techniques

Several surgical techniques have been described to repair partial tears. The technique chosen is influenced by tear location or surgeon preference. Bursal-sided partial-thickness tears are usually completed to full-thickness tears and repaired using suture anchors arthroscopically or by mini-open repair technique. Several recent articles have described techniques by which partial-thickness bursal tears can be repaired arthroscopically.^{73,74} Articular-sided tears can also be completed and repaired as a full-thickness defect or repaired by a “transtendon” technique in which the articular-side fibers are advanced and attached at their anatomic footprint. Intratendinous tears may be reapproximated by suture plication of the delaminated layers and may be advanced to the footprint using suture anchors.

Conversion to Full-Thickness Tears

Repair of most bursal-sided and many articular-sided tears is usually accomplished by conversion to full-thickness tears with or without a subacromial decompression. Preliminary results of arthroscopic repair for partial-thickness tears in the general population are promising.

Deutsch³ recently presented the results of a prospective evaluation of the clinical outcomes of 41 patients (mean age, 49 years) with PTCTs (>50%) treated with arthroscopic conversion to a full-thickness tear and single-row suture anchor repair at a mean follow-up of 38 months. In this nonathlete cohort, significant improvements were noted in ASES scores, ROM, strength, pain relief, function, and satisfaction.

Park and colleagues⁷⁵ reported 34-month average follow-up of arthroscopic repair and decompression in 22 patients with partial-thickness tears compared with 20 patients with full-thickness rotator cuff tears. The technique of arthroscopic repair was based on tear location, with 20 of the 22 PTCTs treated “on the bursal or articular side.” The other 2 were, presumably, converted to full-thickness tears. Both groups demonstrated similar improvements in pain, motion, and function by ASES scores, and 93% of all patients had good-to-excellent results with a 95% rate of satisfactory outcome with regard to pain reduction and functional outcome.

Few studies have examined outcomes of arthroscopic or open repair of full-thickness tears in athletes. The literature contains several recent studies that report a high rate of success in the treatment of partial-thickness rotator cuff tears with arthroscopic rotator cuff repair.^{2,75} Although these data are encouraging, it is worth pointing out that most of these studies have not evaluated high-level overhead athletes, and therefore, one must exercise discretion in extrapolating such results. The few studies in which (full-thickness) cuff tears have been repaired in throwers reinforce this impression. Results of such conversion are limited in the literature, although one might extrapolate results of analogous small non-retracted full-thickness tears.

A recent study by Mazoué and Andrews⁴¹ evaluated the results of mini-open rotator cuff repair in 16 professional baseball players (12 pitchers) at an average 67-month follow-up. Although this cohort included patients with full-thickness tears, they found that only 2 players (1 pitcher and 1 position player) with repairs of their dominant shoulder were able to return to a high competitive level of baseball. Only 1 of the 12 pitchers was able to return to competitive professional baseball. They concluded that it was difficult to return as a pitcher at a high level of competition after repair of

a full-thickness rotator cuff tear of the dominant shoulder, at least by way of a mini-open technique. Whether arthroscopic repair would fare better is unknown.

A similar study by Tibone and colleagues⁷⁶ examined the results of open repair of full-thickness rotator cuff tears in a subset of 5 professional baseball pitchers and reported that 3 (60%) were unable to play professional baseball and 2 (40%) were able to pitch professionally but did so with difficulty.

Transtendon repair

Arthroscopic advances have led to the evolution of the transtendon approach to repair articular-sided partial cuff tears (**Fig. 11**). Lo and Burkhart⁵ described this technique in which the articular cuff footprint is reestablished while preserving intact the bursal portion of the cuff. At a minimum of 1-year follow-up, they reported significant improvement in all 25 patients, with mean UCLA shoulder rating scale scores increasing from 15 preoperatively to 32 postoperatively. Their patient population did not include overhead athletes.

In a technique paper with early results of their first 22 consecutive nonathlete patients, Waibl and colleagues⁷⁷ reported 91% overall good and excellent results. Ide and colleagues⁴ reported their transtendon results in 17 patients at an average of 39-month follow-up, finding 14 good, 1 fair, and no poor results. Of 6 overhead athletes, 2 returned to their previous level, 3 to a lower level, and 1 did not return. At an

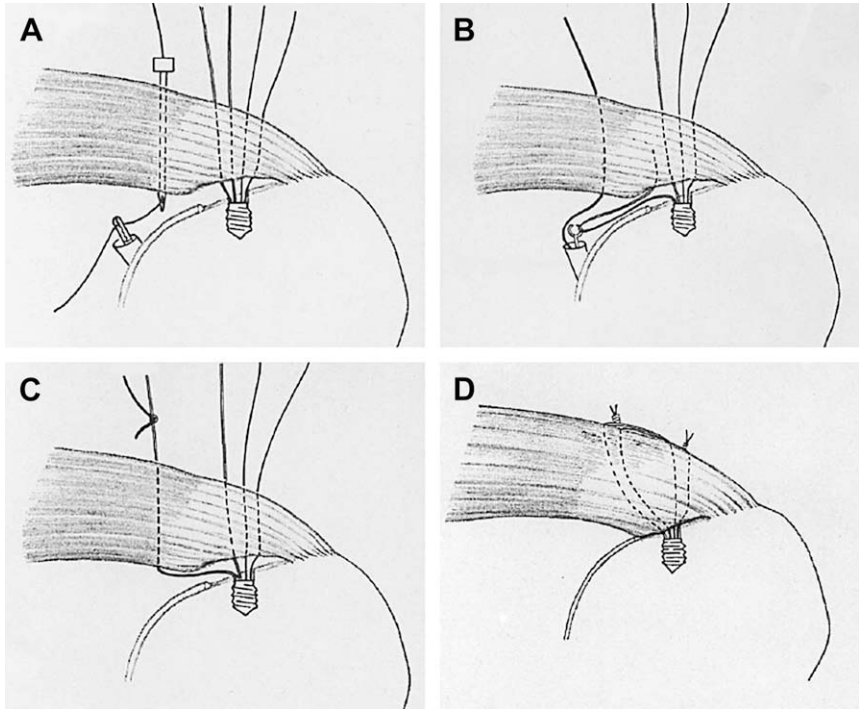


Fig. 11. Transtendon repair of articular-sided cuff tear, in which suture anchor limbs are shuttled percutaneously through the cuff and secured by mattress configuration on the intact bursal surface. (From Ide J, Maeda S, Takagi K. Arthroscopic transtendon repair of partial-thickness articular-side tears of the rotator cuff: anatomic and clinical study. *Am J Sports Med* 2005;33:1672–9; with permission.)

early 14-month average follow-up after transtendon repair, Duralde and Kimmerly⁷⁸ reported good or excellent results in 20 of 24 patients. They did not describe their cohort but they were not throwers.

Transtendon Surgical Technique Using Suture Anchors

1. The patient is placed in the lateral decubitus position with a standard posterior viewing and anterior interval portals.
2. Associated pathology is addressed first before cuff repair.
3. The articular tear, including any intratendinous extension, is debrided back to healthy tissue, and a monofilament-marking suture is placed percutaneously into the center of the defect.
4. The scope is positioned within the subacromial space and a bursectomy performed to evaluate the bursal side of the cuff (directed by the marking suture) and to facilitate subsequent suture knot tying.
5. The scope is repositioned within the glenohumeral joint.
6. If a suture anchor repair is anticipated, the exposed tuberosity footprint is debrided of soft tissue and a burr used to generate a healing response, taking care to limit preparation to the normal anatomic (not medialized) attachment site. In some cases of intratendinous pathology, only the delaminated portion is repaired without using a suture anchor.
7. A soft tissue grasper from the anterior portal grasps the free edge of the debrided cuff and translates it laterally toward the prepared footprint. Arm abduction can facilitate this apposition (**Fig. 12**).
8. Suture anchor(s) are now placed within the tuberosity footprint (**Fig. 13**). The number used and location placed are based on the area of exposed footprint. Anchor placement is adjusted based on tendon involvement, near the articular margin for the supraspinatus, but progressively further away (ie, 3 mm) as the tear extends posteriorly (ie, infraspinatus). Usually only 1 or 2 anchors are used to restore the medial row. Occasionally, a lateral row repair is also performed. In such cases, the lateral row anchors are placed first so that this repair does not interfere with the subsequent medial row repair.
9. Anchors can be placed percutaneously across the muscle–tendon junction of the cuff or through a small defect in the lateral cuff attachment site. Positioning the arm in adduction facilitates anchor placement when using this technique.

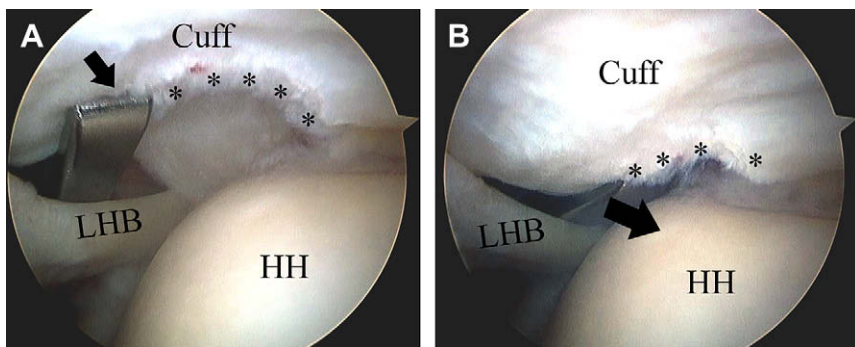


Fig. 12. (A) Soft tissue grasper (*arrow*) through anterior portal grasps free edge of torn articular cuff margin (*) and (B) advances (*arrow*) to footprint of this right shoulder, viewed from posterior portal. HH, humeral head; LHB, long head biceps tendon.

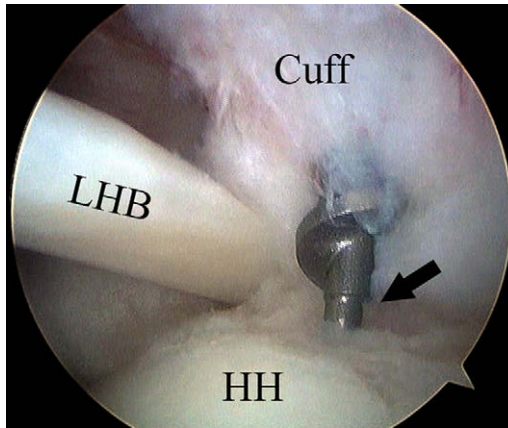


Fig. 13. A metal corkscrew anchor is percutaneously introduced at the lateral margin of the cuff footprint into the tuberosity at the anatomic cuff insertion in this right shoulder viewed from posterior portal. HH, humeral head; LHB, long head biceps tendon.

10. A spinal needle along the acromial margin is used to percutaneously pass monofilament (#1 PDS) suture, directing the needle just medial to the free edge of the debrided cuff tear, at the site of its intended reattachment. Each monofilament suture is then used to shuttle a suture anchor suture limb out the bursal side of the cuff (**Fig. 14**).
11. Step 8 is repeated for the second limb of the same anchor suture.
12. These steps are repeated for all sutures on each anchor and for each anchor, until all sutures have been placed (**Fig. 15**).
13. In cases of intratendinous extension, monofilament sutures can be passed across the delaminated cuff, and permanent (#1 FiberWire) shuttled across in mattress pairs. When tied in the subacromial space, this approximates the delaminated portion of the cuff.
14. The scope is repositioned within the subacromial space and with the arm placed in abduction, the suture limb pairs are securely tied on the bursal side of the cuff (**Fig. 16**).
15. The final repair is inspected from the intra-articular perspective (**Fig. 17**).

Intratendinous repair

Intratendinous extension typically occurs at the posterior supraspinatus/anterior infraspinatus junction and is common in overhead athletes (**Fig. 18**). Several investigators have described the technique by which intratendinous pathology can be addressed by the use of mattress sutures across the delamination and tied in the subacromial space. Intratendinous repair is achieved using mattress sutures to reapproximate the delaminated fibers of the upper and lower leaves of the (usually infraspinatus) cuff, with or without advancement and anchor repair to the tuberosity footprint. Advantages of this technique include fixation to intact bursal-sided cuff fibers and sealing the intratendinous delaminated component to minimize risk for tear propagation and progression.

In 2001, Conway² reported his experience repairing deep intratendinous partial-thickness tears using a transtendinous technique in a group of 14 baseball players (13 pitchers and 1 outfielder) (**Fig. 19**). Of the 9 players followed more than a year from surgery (7 professionals and 2 college students), 8 (89%) returned to play at

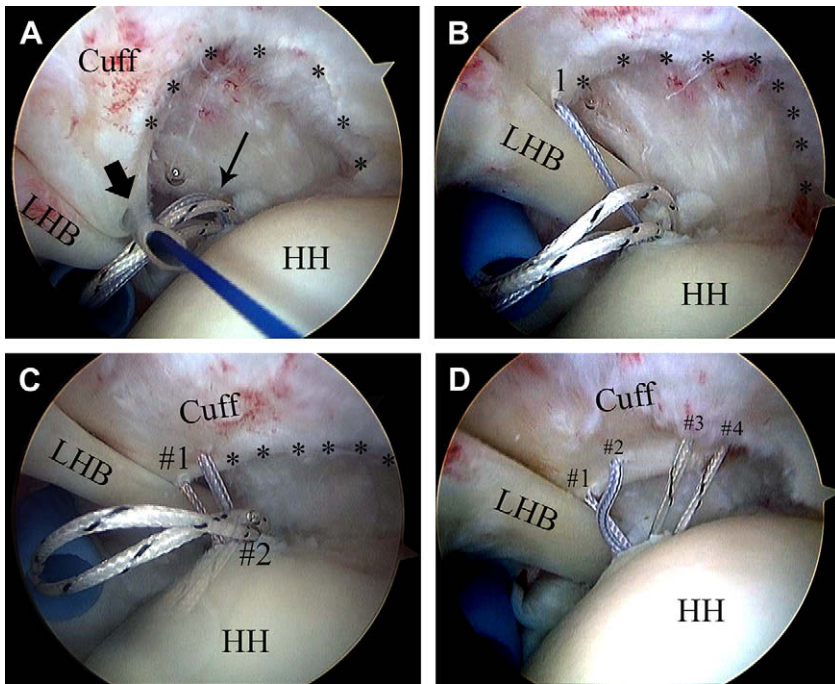


Fig. 14. (A) The percutaneously placed spinal needle (*arrow*) through which monofilament suture is shuttled into the joint, as viewed in the right shoulder through posterior portal. *cuff tear margin; HH, humeral head; LHB, long head biceps tendon, thin arrow, anchor FiberWire sutures. (B) Appearance after shuttling first FiberWire suture (1). (C) Appearance after shuttling first pair of FiberWire suture (#1), with second pair of same anchor (#2) not yet passed. (D) Appearance after passing all 4 FiberWire limbs (#1–4) from first anterior suture anchor.

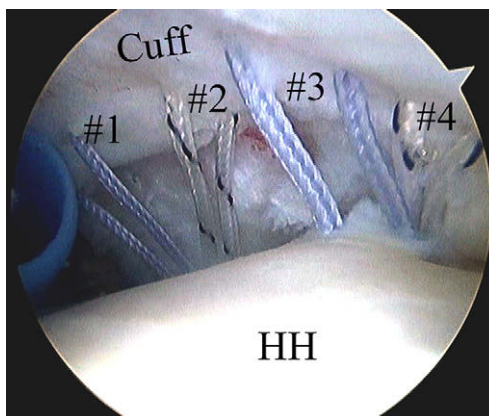


Fig. 15. FiberWire suture limbs from 2 medial footprint anchors have been passed through debrided articular cuff margin, in this right shoulder viewed from posterior portal. #1–4 each of 4 suture pairs; HH, humeral head.

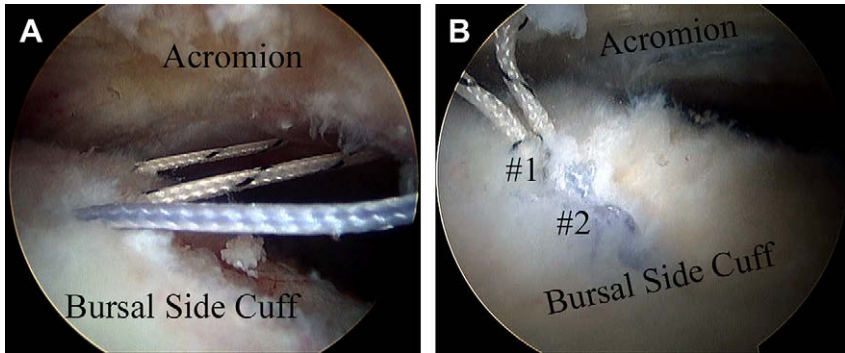


Fig. 16. (A) All passed FiberWire sutures are visualized in the subacromial space in this right shoulder viewed from posterior portal. (B) Final appearance in subacromial space after tying all pairs.

the same or higher level. However, all had posterior-superior labral pathology, half had anterior instability, and 57% demonstrated hypertrophic subacromial bursa.

Brockmeier and colleagues⁶ recently presented their technique of arthroscopic intratendinous repair for delaminated partial-thickness tears in high-level overhead athletes. At early follow-up of 5 months, the investigators noted encouraging results and reported that longer-term follow-up is necessary. Their technique is similar to that used by Conway² who reported an 89% return to the same or higher level of play in a small series of baseball players who underwent arthroscopic mattress suture repair of intratendinous partial-thickness tears. However, patients in this study group had additional injuries, including superior labral tears, anterior instability, and hypertrophic subacromial bursa, which were also addressed and likely affected the final results.

Intratendinous Surgical Technique

With the scope in the glenohumeral joint, and having already addressed any associated pathology and performed a bursectomy in the subacromial space, spinal needles are used to pass the suture across the delaminated split.

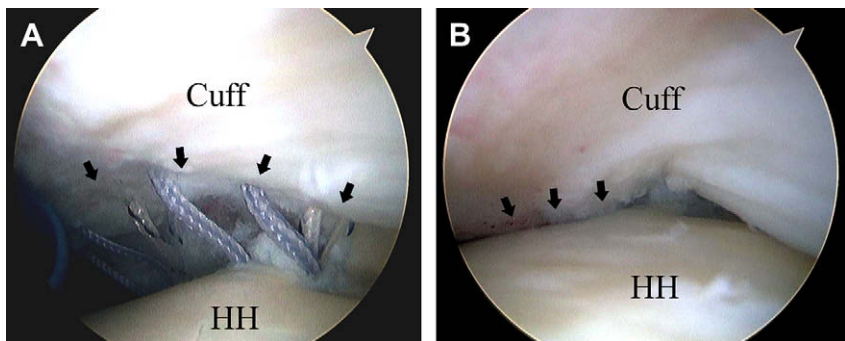


Fig. 17. (A) Intra-articular view of cuff after transtendon sutures have been passed just medial to the torn cuff's margin (arrows) but not yet tied in this right shoulder, viewed from posterior portal. HH, humeral head. (B) Appearance after tying sutures over intact bursal side in subacromial space. Not the apposition of the torn cuff margin to the anatomic footprint (arrows).

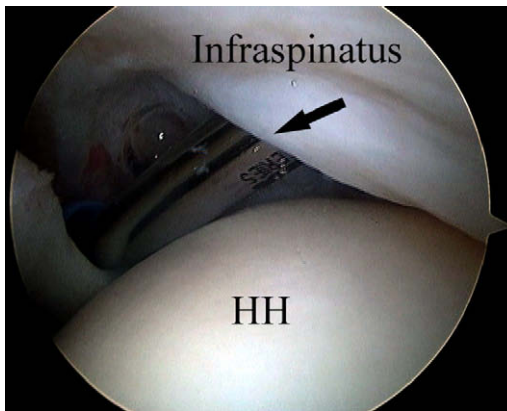


Fig. 18. Intratendinous tear extension into the infraspinatus is debrided in this right shoulder, viewed from a posterior arthroscopic portal. Arrow, shaver blade; HH, humeral head.

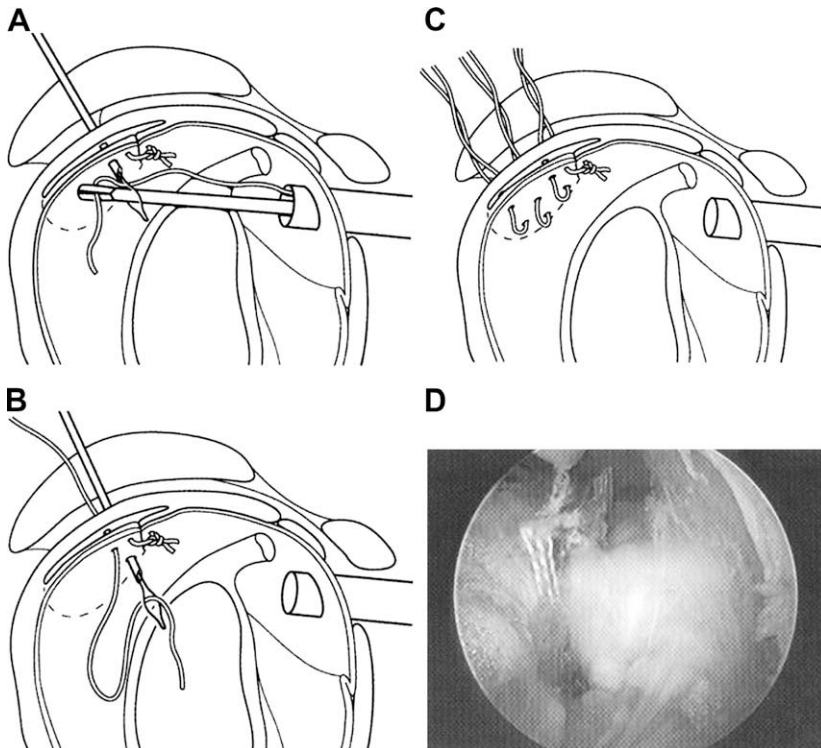


Fig. 19. Technique by which transtendinous repair of an intratendinous split is performed. (A) A wire loop is passed through a spinal needle, retrieving a suture that is shuttled back through the bursal side of the tendon. (B) A second spinal needle with loop is passed, retrieving the other end of the first passed suture. (C) Three suture pairs have been passed and are ready to be tied in the subacromial space, reapproximating the split. Bottom right (D) shows the completed repair from the subacromial space. (From Conway JE. Arthroscopic repair of partial-thickness rotator cuff tears and SLAP lesions in professional ball players. *Orthop Clin North Am* 2001;32:443–56; with permission.)

1. While the cuff is held reduced using a soft tissue grasper from the anterior scope portal, a spinal needle is introduced off the acromial edge and directed across the cuff's intratendinous split.
2. Monofilament suture (#1 PDS) is shuttled through the needle, retrieved, and withdrawn from the anterior interval portal.
3. A permanent (#1 Arthrex FiberWire, Naples, FL) suture is then retrograde shuttled back across the tendon and out the skin.
4. A second spinal needle monofilament suture is passed through the tendon layers 3 to 5 mm from the first suture, retrieved out of the anterior cannula, and the other limb of the already passed FiberWire suture shuttled across the tendon, effectively making a mattress suture.
5. Steps 2 to 5 are repeated until the split has been satisfactorily approximated.
6. The scope is repositioned within the subacromial space and the mattress sutures tied.
7. The final repair is inspected from the intra-articular perspective.

Transtendon and intratendon repairs undergo similar postoperative protocols intended to protect the cuff repair early in the recovery (**Table 1**).

REPAIR IN OVERHEAD ATHLETES

Despite the enthusiasm for repairing partial-thickness defects, the benefit to overhead throwers remains unclear. The problem in this group of high-demand athletes lies in knowing the degree to which anatomy ought to be restored to "normal." Although repair of the intratendinous portion of the cuff may have merit, advancement of the articular defect to the tuberosity risks over-constraining the joint and decreasing the muscle-tendon length of the cuff. Nonanatomic repair using suture anchors carries with it a significant risk for medializing the cuff insertion and may alter shoulder anatomy and mechanics. Consequently, in selected throwers, caution should be used in repairing the cuff unless significantly (>75%) torn. In cases of intratendinous pathology, limited repair of intratendinous pathology without using suture anchors to reattach the cuff to the footprint should be considered.

TREATMENT ALGORITHM

Operative treatment can be based on whether the athlete is a thrower or a nonthrower (**Table 2**). For nonthrowers with a grade I tear, estimated to be less than 35% thickness, debridement is performed, and when necessary, a subacromial decompression is done. For a grade II tear, if the tendon tear is between 35% and 75% thickness,

Table 1 Postoperative protocol after transtendon or intratendon repair
Postoperative Protocol
The arm is kept in an ultra-sling for 3 wk, permitting active and assistive ROM hand, wrist, elbow, and scapular stabilization exercises.
Passive ROM exercises are begun at week 3.
Active ROM exercises are begun at 6 wk.
Light and progressive resistance at 12 wk.
Throwing program begins at 16 wk (presuming restoration of motion, strength, rhythm).
Return to throwing 6–10 mo.

Table 2 Treatment algorithm	
Nonthrowers	Throwers
Grade 1, <35% torn—debridement ± ASAD prn	Depth of articular-sided tear
Grade 2, 35%–75% torn—transtendon repair	<75%—debridement only
Grade 3, >75% torn—transtendon repair	>75%—consider arthroscopic repair
	Consider supraspinatus repair earlier than infraspinatus
	Intratendinous segment
	Thin or <1 cm: resect AS segment
	Thick or >1 cm: consider mattress repair ± anchor repair
	Depth of intratendinous segment
	1–2 cm: consider arthroscopic repair (with or without anchor)
	>2 cm: consider mini-open repair

Abbreviations: AS, articular side; ASAD, arthroscopic sub-acromial decompression.

a transtendon repair is performed. If the tear depth exceeds 75% completing the tear and performing an arthroscopic cuff repair is considered.

In throwers, the threshold for repair is considerably higher. The depth of the tear and the depth and quality of the intratendinous segment are taken into account. If the depth of the articular-sided tear is less than 75%, a debridement alone is performed. When the tear is greater than 75%, transtendon repair and supraspinatus tears earlier than infraspinatus tears are considered. If the intratendinous segment is thin or less than 1 cm, debridement of the articular segment alone is done. If it is thick or exceeds 1 cm, a mattress intratendon repair with or without an anchor is considered. Finally, if the depth of the intratendinous segment is 1 to 2 cm, then an arthroscopic repair is performed. If it exceeds 2 cm, a mini-open repair using suture anchors is done.

SUMMARY

Partial-thickness tears of the rotator cuff pose a unique challenge to those caring for athlete's shoulder. Their clinical presentation is variable; some athletes are symptom-free and function despite significant MR abnormalities. Others demonstrate considerable impairment even in the face of a small tear. This setting is further complicated by the frequent association with a spectrum of other pathologies, including instability and subacromial and internal impingement. Although there is evidence that partial tears progress, not all do, and the functional accommodation to these lesions, even at the highest level of throwing, cautions against unnecessary intervention. Recent advances in evaluation and imaging strategies have improved the ability to detect these lesions, and refinements in arthroscopic repair techniques have furthered the ability to restore the cuff footprint anatomically. Yet, despite awareness and recently evolved surgical prowess, current treatment guidelines and recommendations remain empiric. Treatment must, therefore, be individualized based on many factors. Nonoperative treatment is an effective strategy for many athletes. When necessary, debridement seems to be an effective option for those whose partial tears approach 50% of the tendon's thickness. However, in overhead throwers, in whom anatomic restoration may preclude their return to effective throwing, the threshold for repair is considerably higher. Only with further investigation and longer follow-up of current techniques can the correct indications for treating athlete's partial cuff tears be determined with greater precision.

REFERENCES

1. Connor PM, Banks DM, Tyson AB, et al. Magnetic resonance imaging of the asymptomatic shoulder of overhead athletes: a 5-year follow-up study. *Am J Sports Med* 2003;31:724–7.
2. Conway JE. Arthroscopic repair of partial-thickness rotator cuff tears and SLAP lesions in professional baseball players. *Orthop Clin North Am* 2001;32:443–56.
3. Deutsch A. Arthroscopic repair of partial-thickness tears of the rotator cuff. *J Shoulder Elbow Surg* 2007;16:193–201.
4. Ide J, Maeda S, Takagi K. Arthroscopic transtendon repair of partial-thickness articular-side tears of the rotator cuff: anatomical and clinical study. *Am J Sports Med* 2005;33:1672–9.
5. Lo IKY, Burkhart SS. Transtendon arthroscopic repair of partial-thickness, articular surface tears of the rotator cuff. *Arthroscopy* 2004;20:214–20.
6. Brockmeier SF, Dodson CC, Gamradt SC, et al. Arthroscopic intratendinous repair of the delaminated partial-thickness rotator cuff tear in overhead athletes. *Arthroscopy* 2007 [epub ahead of print].
7. Codman EA. *The shoulder*. Boston: Thomas Todd; 1934.
8. Teefey SA, Rubin DA, Middleton WD, et al. Detection and quantification of rotator cuff tears: comparison of ultrasonographic, magnetic resonance imaging, and arthroscopic findings in seventy-one consecutive cases. *J Bone Joint Surg Am* 2004;86:708–16.
9. Miniaci A, Mascia AT, Salonen DC, et al. Magnetic resonance imaging of the shoulder in asymptomatic professional baseball pitchers. *Am J Sports Med* 2002;30:66–73.
10. Lohr JF, Uthoff HK. The microvascular pattern of the supraspinatus tendon. *Clin Orthop Relat Res* 1990;254:35–8.
11. Yamanaka K, Fukuda H. Pathologic studies of the supraspinatus tendon with reference to incomplete partial thickness tear. In: Takagishi N, editor. *The shoulder*. Tokyo (Japan): Professional Postgraduate Services; 1987. p. 220–4.
12. Payne LZ, Altchek DW, Craig EV, et al. Arthroscopic treatment of partial rotator cuff tears in young athletes. A preliminary report. *Am J Sports Med* 1997;25:299–305.
13. Fukuda H, Hamada K, Yamanaka K. Pathology and pathogenesis of bursal-side rotator cuff tears viewed from en bloc histologic sections. *Clin Orthop Relat Res* 1990;254:75–80.
14. Uthoff HK, Sano H. Pathology of failure of the rotator cuff tendon. *Orthop Clin North Am* 1997;28(1):31–41.
15. Fukuda H. The management of partial-thickness tears of the rotator cuff. *J Bone Joint Surg Br* 2003;85:3–11.
16. Gartsman GM, Milne JC. Articular surface partial-thickness rotator cuff tears. *J Shoulder Elbow Surg* 1995;4:409–15.
17. Nho SJ, Yadav H, Shindle MK, et al. Rotator cuff degeneration: etiology and pathogenesis. *Am J Sports Med* 2008;36:987–93.
18. Mazzocca AD, Rincon LM, O'Connor RW, et al. Intra-articular partial-thickness rotator cuff tears: analysis of injured and repaired strain behavior. *Am J Sports Med* 2008;36:110–6.
19. Moseley HF, Goldie I. The arterial pattern of the rotator cuff of the shoulder. *J Bone Joint Surg Br* 1963;45:780–9.
20. Rathbun JB, MacNab I. The microvascular pattern of the rotator cuff. *J Bone Joint Surg Br* 1970;52:540–3.

21. Rudzki JR, Adler RS, Warren RF, et al. Contrast-enhanced ultrasound characterization of the vascularity of the rotator cuff tendon: age- and activity-related changes in the intact asymptomatic rotator cuff. *J Shoulder Elbow Surg* 2008; 17:96S–100S.
22. Lohr JF, Uhthoff HK. The pathogenesis of degenerative rotator cuff tears. *Orthop Trans* 1987;11:237.
23. Clark JM, Harryman DT. Tendons, ligaments, and capsule of the rotator cuff: gross and microscopic anatomy. *J Bone Joint Surg Am* 1992;74:713–25.
24. Ruotolo C, Fow JE, Nottage WM. The supraspinatus footprint: an anatomic study of the supraspinatus insertion. *Arthroscopy* 2004;20:246–9.
25. Davidson PA, Elattrache NS, Jobe CM, et al. Rotator cuff and posterior-superior glenoid labrum injury associated with increased glenohumeral motion: a new site of impingement. *J Shoulder Elbow Surg* 1995;4:384–90.
26. Neer CS II. Impingement lesions. *Clin Orthop Relat Res* 1983;173:70–7.
27. Kvitne RS, Jobe FW, Jobe CM. Shoulder instability in the overhand or throwing athlete. *Clin Sports Med* 1995;14:917–35.
28. Walch G, Liotard JP, Boileau P, et al. Postero-superior impingement in the throwing athlete. *J Shoulder Elbow Surg* 1992;1:238–45.
29. Walch G, Boileau P, Noel E, et al. Impingement of the deep surface of the supraspinatus tendon on the posterosuperior glenoid rim: an arthroscopic study. *J Shoulder Elbow Surg* 1992;1:238–45.
30. Burkhart SS, Morgan CD, Kibler WB. The disabled throwing shoulder: spectrum of pathology. Part I: pathoanatomy and biomechanics. *Arthroscopy* 2003;19: 404–20.
31. Sonnery-Cottet B, Edwards TB, Noel E, et al. Results of arthroscopic treatment of posterosuperior glenoid impingement in tennis players. *Am J Sports Med* 2002; 30:227–32.
32. Meister K, Seroyer S. Arthroscopic management of the thrower's shoulder: internal impingement. *Orthop Clin North Am* 2003;34:539–47.
33. Ellman H. Diagnosis and treatment of incomplete rotator cuff tears. *Clin Orthop Relat Res* 1990;(254):64–74.
34. Ryu RK, Dunbar WH, Kuhn JE, et al. Comprehensive evaluation and treatment of the shoulder in the throwing athlete. *Arthroscopy* 2002;18:70–89.
35. Itoi E, Tabata S. Incomplete rotator cuff tears. Results of operative treatment. *Clin Orthop Relat Res* 1992;284:128–35.
36. Weber SC. Arthroscopic debridement and acromioplasty versus mini-open repair in the management of significant partial-thickness tears of the rotator cuff. *Orthop Clin North Am* 1997;28:79–82.
37. Matava MJ, Purcell DB, Rudzki JR. Partial-thickness rotator cuff tears. *Am J Sports Med* 2005;33(9):1405–17.
38. Snyder SJ, Pachelli AF, Del Pizzo W, et al. Partial thickness rotator cuff tears: results of arthroscopic treatment. *Arthroscopy* 1991;7:1–7.
39. Crockett HC, Gross LB, Wilk KE, et al. Osseous adaptation and range of motion at the glenohumeral joint in professional baseball pitchers. *Am J Sports Med* 2002; 30:20–6.
40. Fukuda H, Hamada K, Nakajima T, et al. Pathology and pathogenesis of the intra-tendinous tearing of the rotator cuff viewed from en bloc histologic sections. *Clin Orthop Relat Res* 1994;304:60–7.
41. Mazoué CG, Andrews JR. Repair of full-thickness rotator cuff tears in professional baseball players. *Am J Sports Med* 2006;34:182–9.

42. Nakajima T, Rokuuma N, Hamada K, et al. Histologic and biomechanical characteristics of the supraspinatus tendon: reference to rotator cuff tearing. *J Shoulder Elbow Surg* 1994;3:19–87.
43. Bey MJ, Ramsey ML, Soslowsky LJ. Intratendinous strain fields of the supraspinatus tendon: effect of a surgically created articular surface rotator cuff tear. *J Shoulder Elbow Surg* 2002;11:562–9.
44. Reilly P, Amis AA, Wallace AL, et al. Supraspinatus tears: propagation and strain alteration. *J Shoulder Elbow Surg* 2003;12:134–8.
45. Dugas JR, Campbell DA, Warren RF, et al. Anatomy and dimensions of rotator cuff insertions. *J Shoulder Elbow Surg* 2002;11:498–503.
46. Burkhart SS, Morgan CD, Kibler WB. The disabled throwing shoulder: spectrum of pathology part III: the SICK scapula, scapular dyskinesis, the kinetic chain, and rehabilitation. *Arthroscopy* 2003;19:641–61.
47. Kibler WB, Sciascia A, Dome D. Evaluation of apparent and absolute supraspinatus strength in patients with shoulder injury using the scapular retraction test. *Am J Sports Med* 2006;34(10):1643–7.
48. Neer CS II. Anterior acromioplasty for the chronic impingement syndrome in the shoulder: a preliminary report. *J Bone Joint Surg Am* 1972;67:41–50.
49. MacDonald PB, Clark P, Sutherland K. An analysis of the diagnostic accuracy of the Hawkins and Neer subacromial impingement signs. *J Shoulder Elbow Surg* 2000;9:299–301.
50. Meister K. Current concepts: injuries to the shoulder in the throwing athlete, part two: evaluation/treatment. *Am J Sports Med* 2000;28(4):587–601.
51. Hamner DL, Pink MM, Jobe FW. A modification of the relocation test: arthroscopic findings associated with a positive test. *J Shoulder Elbow Surg* 2000;9:263–7.
52. Zaslav K. Internal rotation resistance strength test: a new diagnostic test to differentiate intra-articular pathology from outlet (Neer) impingement syndrome in the shoulder. *J Shoulder and Elbow Surg* 2001;10(1):23–7.
53. Tennent TD, Beach WR, Meyers JF. A review of the special tests associated with shoulder examination. Part I: The rotator cuff tears. *Clinical Sports Medicine Update*. *Am J Sports Med* 2003;31(1):154–60.
54. Valadie AL III, Jobes CM, Pink MM. Anatomy of provocative tests for impingement syndrome of the shoulder. *J Shoulder Elbow Surg* 2000;9:36–46.
55. O'Brien SJ, Pagnani MJ, Fealy S, et al. The active compression test: a new and effective test for diagnosing labral tears and acromioclavicular joint abnormally. *Am J Sports Med* 1998;26:610–3.
56. Nakagawa S, Yoneda M, Hayashida K, et al. Greater tuberosity notch: an important indicator of articular-side partial rotator cuff tears in the shoulders of throwing athletes. *Am J Sports Med* 2001;29:762–70.
57. van Holsbeeck MT, Kolowich PA, Eyler WR, et al. Ultrasound depiction of partial-thickness tear of the rotator cuff. *Radiology* 1995;197:443–6.
58. Wiener SN, Seitz WH Jr. Sonography of the shoulder in patients with tears of the rotator cuff: accuracy and value for selecting surgical options. *AJR Am J Roentgenol* 1993;160:103–7.
59. Traugher PD, Goodwin TE. Shoulder MRI. arthroscopic correlation with emphasis on partial tears. *J Comput Assist Tomogr* 1992;16:129–33.
60. Tuite MJ, Yandow DR, DeSmet AA, et al. Diagnosis of partial and complete rotator cuff tears using combined gradient echo and spin echo imaging. *Skeletal Radiol* 1994;23:541–5.
61. Lee SY, Lee JK. Horizontal component of partial-thickness tears of rotator cuff: imaging characteristics and comparison of ABER view with oblique

- coronal view at MR arthrography initial results. *Radiology* 2002;224(2):470–6.
62. Meister K, Thesing J, Montgomery WJ, et al. MR arthrography of partial thickness tears of the undersurface of the rotator cuff: an arthroscopic correlation. *Skeletal Radiol* 2004;33:136–41.
 63. Yamanaka K, Matsumoto T. The joint side tear of the rotator cuff. *Techniques in Shoulder & Elbow Surgery* 1994;304:68–73.
 64. Hiroaki Fukuda MD. Partial-thickness rotator cuff tears: a modern view on Codman's classic. *J Shoulder Elbow Surg* 2000;9:163–8.
 65. Nicholson GP. Arthroscopic acromioplasty: a comparison between workers' compensation and non-workers' compensation populations. *J Bone Joint Surg Am* 2003;85:682–9.
 66. Budoff JE, Nirschl RP, Guidi EJ. Debridement of partial-thickness tears of the rotator cuff without acromioplasty. Long-term follow-up and review of the literature. *J Bone Joint Surg Am* 1998;80:733–48.
 67. Esch JC, Ozerkis LR, Helgager JA, et al. Arthroscopic subacromial decompression: results according to the degree of rotator cuff tear. *Arthroscopy* 1988;4:241–9.
 68. Weber SC. Arthroscopic debridement and acromioplasty versus mini-open repair in the treatment of significant partial-thickness rotator cuff tears. *Arthroscopy* 1999;15:126–31.
 69. Cordasco FA, Backer M, Craig EV, et al. The partial-thickness rotator cuff tear: is acromioplasty without repair sufficient? *Am J Sports Med* 2002;30:257–60.
 70. Andrews JR, Broussard TS, Carson WG. Arthroscopy of the shoulder in the management of partial tears of the rotator cuff: a preliminary report. *Arthroscopy* 1985;1:117–22.
 71. Kim SH. Arthroscopic management of partial thickness cuff tears. *AAOS Poster* 2005.
 72. Spencer EE Jr, Dunn WR, Wright RW. Interobserver agreement in the classification of rotator cuff tears using magnetic resonance imaging. *Am J Sports Med* 2008;36:99–103.
 73. Yoo JC, Ahn JH, Lee SH, et al. Arthroscopic full-layer repair of bursal-side partial-thickness rotator cuff tears: a small-window technique. *Arthroscopy* 2007;23(8):903.e1–4.
 74. Wolff AB, Magit DP, Miller SR, et al. Arthroscopic fixation of bursal-sided rotator cuff tears. *Arthroscopy* 2006;22:1247.
 75. Park JY, Chung KT, Yoo MJ. A serial comparison of arthroscopic repairs for partial- and full-thickness rotator cuff tears. *Arthroscopy* 2004;20:705–11.
 76. Tibone JE, Elrod B, Jobe FW, et al. Surgical treatment of tears of the rotator cuff in athletes. *J Bone Joint Surg Am* 1986;68:887–91.
 77. Waibl B, Buess E. Technical note: partial-thickness articular surface supraspinatus tears: a new transtendon suture technique. *Arthroscopy* 2005;21(3):376–81.
 78. Duralde XA, Kimmerly S. The technique of arthroscopic repair of partial thickness rotator cuff tears. *Techn Shoulder Elbow Surg* 2005;6(2):116–23.