

PSEUDARTHROSIS OF A THIRTY-NINE-YEAR-OLD DENS FRACTURE CAUSING MYELOPATHY

A CASE REPORT

BY JONAS R. RUDZKI, MD, MS, LAWRENCE G. LENKE, MD, KATHY BLANKE, RN, AND K. DANIEL RIEW, MD

Investigation performed at the Washington School of Medicine, Saint Louis, Missouri

Treatment of fractures of the odontoid process of the axis (the dens) has the potential to stabilize a critical injury or result in a high degree of morbidity or even death. We present the case of a patient in whom myelopathy developed more than thirty-nine years after he sustained a dens fracture while playing football. This case is unique because of the prolonged asymptomatic interval between the injury and the development of the myelopathy, during which time the patient worked as a manual laborer. The late onset of progressive myelopathy after a dens fracture is considered uncommon^{1,2} and, to our knowledge, this case represents the second longest delay between a dens fracture and the onset of myelopathy in the English-language literature. The myelopathy resolved after surgical stabilization, and the four-year clinical and radiographic follow-up data are presented. Our patient was notified that data concerning this case would be submitted for publication.

Case Report

A fifty-five-year-old man who performed manual labor working as a machine operator presented to an orthopaedic surgeon with a chief symptom of difficulty using his upper and lower limbs. He reported the insidious onset of increasing neck pain at the base of the skull over the preceding several years, which had been associated with progressively worsening bilateral upper and lower-extremity weakness for the previous three months. The patient had been unable to work or participate in his normal activities of daily living for approximately two months because of the arm weakness. The musculoskeletal history revealed that he had sustained a cervical spine fracture at the age of sixteen years while playing football, which was treated with a neck brace for approximately three months.

On physical examination, the patient appeared to be a well-developed, well-nourished man with a range of motion of the neck of 45° of rotation bilaterally as well as the ability to perform chin-to-chest flexion and vertical extension to neutral. Marked weakness was identified in the upper and lower extremities bilaterally, with 3+ to 4- (of 5) global strength of the upper extremities and 4+ to 5- global strength of the lower extremities. The reflexes were symmetrical in the upper

and lower extremities, and the patient had continuous clonus in the right ankle with three beats in the left ankle. He had decreased light-touch sensation in the ulnar distribution of the left upper extremity. The results of Babinski testing were equivocal bilaterally. Proprioception was within normal limits in the fingers and toes bilaterally, and the gait was normal. The Hoffmann sign was negative, and he had no evidence of difficulty performing rapid alternating movements.

Anteroposterior, lateral, and flexion-extension radiographs of the cervical spine demonstrated a chronic Anderson and D'Alonzo³ type-II dens fracture with marked subluxation of 2 cm (Figs. 1-A and 1-B). Forward flexion made the subluxation slightly worse, whereas extension reduced it by approximately 1 cm. Magnetic resonance imaging of the cervical spine revealed a reduced space for the spinal cord, with several views revealing a tight constriction of the spinal canal at the C1-C2 cervical vertebral levels as well as mild C3-C4 stenosis (Figs. 2-A, 2-B, and 2-C). The diameter of the space available for the spinal cord measured 5 × 12 mm at the level of the most severe stenosis, and a signal change indicative of chronic spinal cord irritation was identified at this level.

The patient was diagnosed as having an ununited type-II dens fracture with anterior subluxation and spinal cord impingement resulting in progressive myelopathy. He was taken to the operating room for placement of a halo vest and subsequent closed reduction under cervical traction while he was awake. The halo ring was placed and, under fluoroscopic guidance, gentle traction was added in 5-lb (2.3-kg) increments to a total of 25 lb (11.3 kg). By keeping the neck in extension, it was possible to partially reduce the subluxation. The partial reduction was confirmed radiographically, and the halo ring was secured to the vest.

For definitive treatment, the patient underwent open reduction of the C2 vertebral fracture-subluxation through a posterior approach two days later. A posterior arthrodesis of C1 and C2 was accomplished with use of autogenous iliac crest bone graft and was secured with atlantoaxial cable wiring. Open reduction was accomplished by posterior translation of the C1 arch by means of the sublaminar cables, and a 4.0-diameter fully threaded transarticular screw was placed

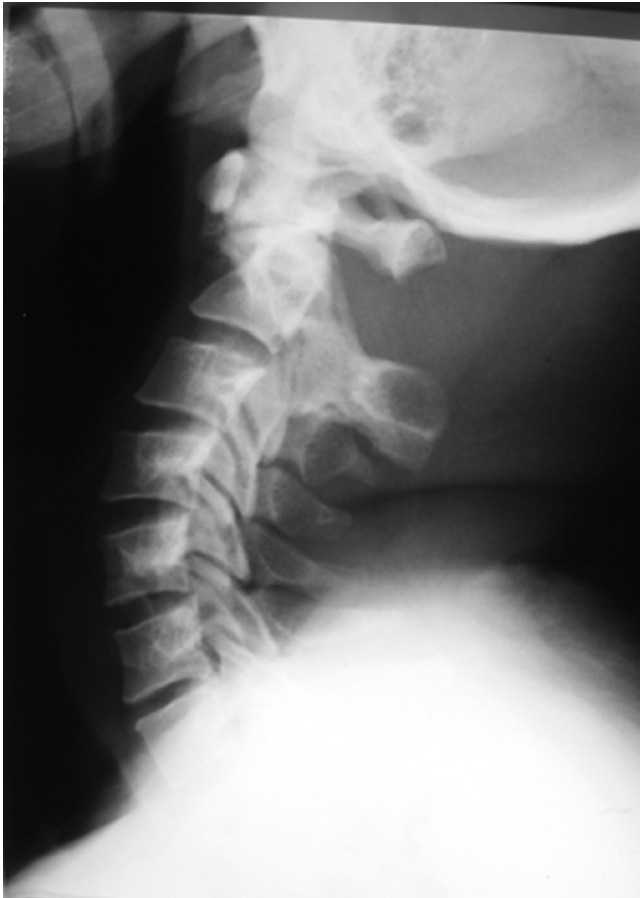

Fig. 1-A

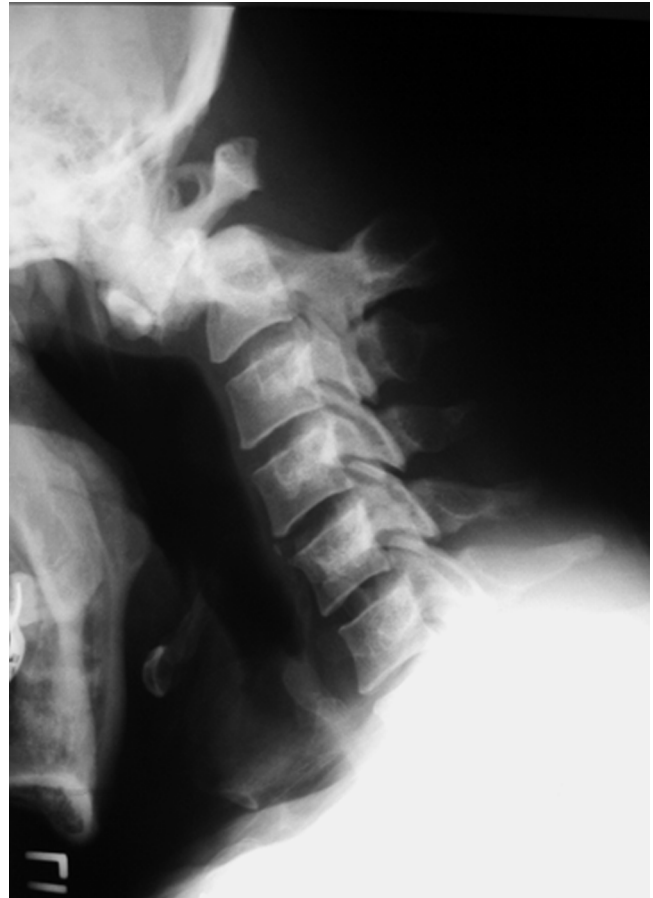

Fig. 1-B

Neutral (Fig. 1-A) and flexion (Fig. 1-B) plain lateral radiographs made at presentation of the myelopathy. The maximal atlantodental interval on the neutral radiograph measures 4 mm, and the space available for the cord measures 6 mm.

through the right C2 vertebral pars interarticularis across the C1 and C2 vertebral facets for fixation. The patient tolerated the procedure well and had an uneventful postoperative course. Intravenous dexamethasone was administered in the perioperative period. As a result of the degree of force required to reduce the fracture and the relatively poor bone density, it was thought that the patient would benefit from the use of the halo vest for an additional ten weeks. The upper and lower-extremity strength returned to normal within three months postoperatively and the clonus resolved as well, allowing him to return to work as a laborer.

Four years after the spine operation, the patient returned for follow-up and reported new-onset left-sided neck pain. He stated that he had no weakness or paresthesias in the upper or lower extremities. On physical examination, he had approximately 40° of neck rotation bilaterally, was able to perform chin-to-chest flexion, and had vertical extension of approximately 20° past neutral. The neurologic examination revealed 5 of 5 upper and lower-extremity strength bilaterally with a normal gait. Radiographs revealed a solid C1-C2 fusion with no evidence of abnormal alignment or instability (Figs. 3-A and 3-B). A cervical magnetic resonance imaging scan

made at this time revealed adequate space for the spinal cord and cervical roots, but there was mild multilevel spondylosis and signal change in the cervical spinal cord consistent with myelomalacia. The patient was referred to a physical therapist, and the pain resolved without additional intervention.

Discussion

Dens fractures account for approximately 7% to 13% of all cervical spine fractures^{4,5}. An estimated 25% to 40% of individuals who sustain this injury do not survive^{6,7}. It has been estimated that only 65% of those who do survive the initial injury seek medical advice, primarily because of neck pain⁸, and even with prompt diagnosis of the injury only 18% to 25% are found to have immediate neurological disability². The natural history of untreated dens fractures has not been definitively elucidated. The literature contains reports of delayed-onset myelopathy as long as forty-five years after the fracture^{1,2}.

The Anderson and D'Alonzo classification system, which is based on the location of the fracture, has been valuable in relation to making a prognosis and planning management of the injury³. The most common type of dens fracture is type II⁹. The mechanism of injury resulting in dens fractures has

been studied extensively¹⁰⁻¹⁴. In series ranging in size from fifteen to 227 dens fractures, rates of nonunion have ranged from 5% (in a series of sixty-three fractures reported by Amyes and Anderson¹⁵) to 64% (in a series of twenty-two fractures described by Schatzker et al.¹¹). Nonunion rates between these extremes have included 28% in a series of thirty-five

fractures reported by Anderson and D'Alonzo³ and 44% in a series of twenty-six fractures described by Nachemson⁸. The nonunion rate following nonoperative management of type-II fractures was 20% in a series of forty-six fractures reported by Seybold and Bayley¹⁶, 32% in a series of ninety-six patients reported by Clark and White¹⁰, 49% in a series of thirty-three frac-

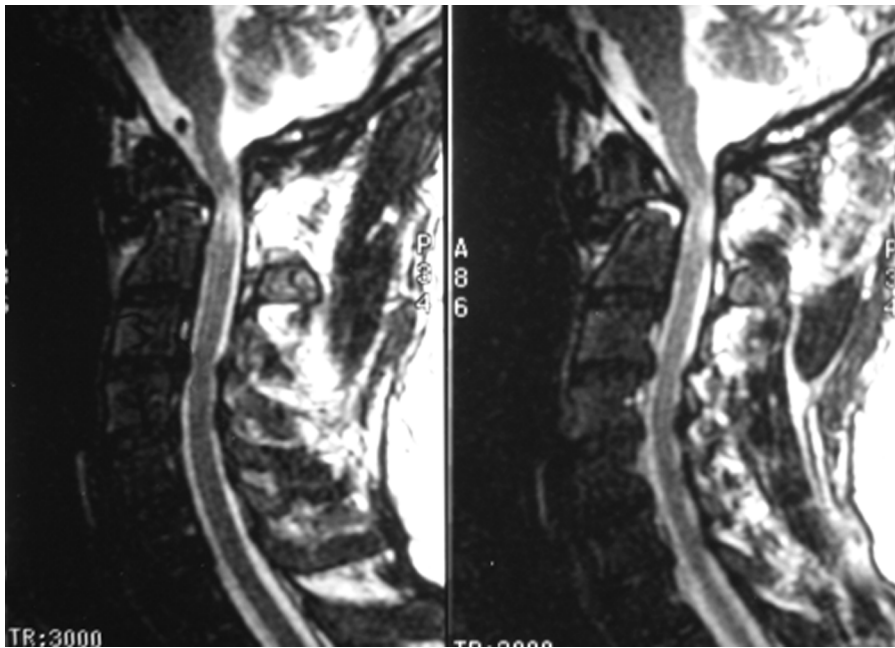


Fig. 2-A

Figs. 2-A, 2-B, and 2-C T2-weighted magnetic resonance images demonstrating a displaced type-II dens fracture with canal compromise and bright spinal cord signal change consistent with edema. The anteroposterior space available for the cord measures 5 mm.

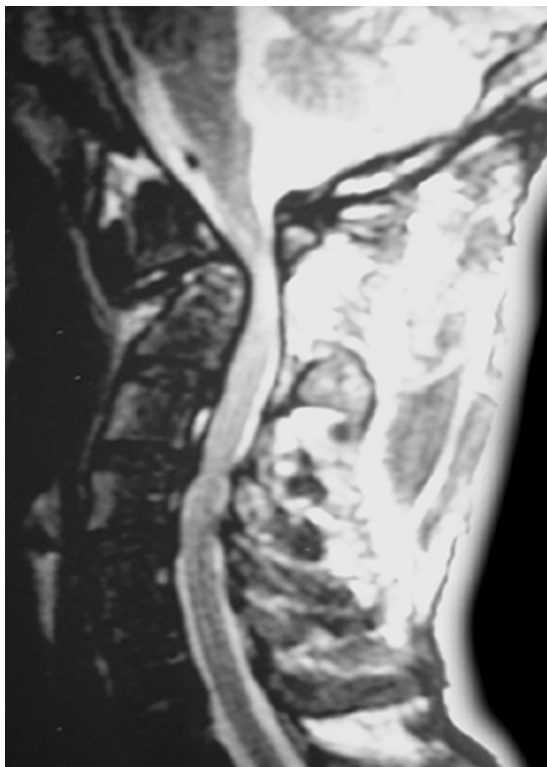


Fig. 2-B

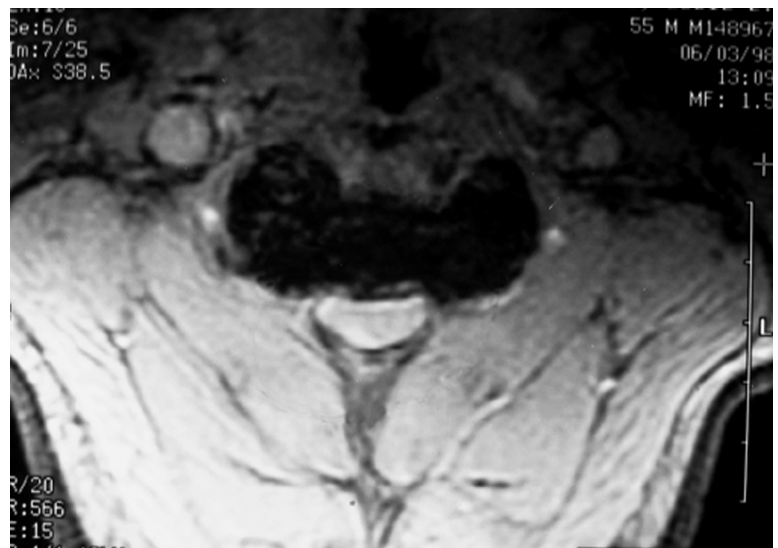


Fig. 2-C

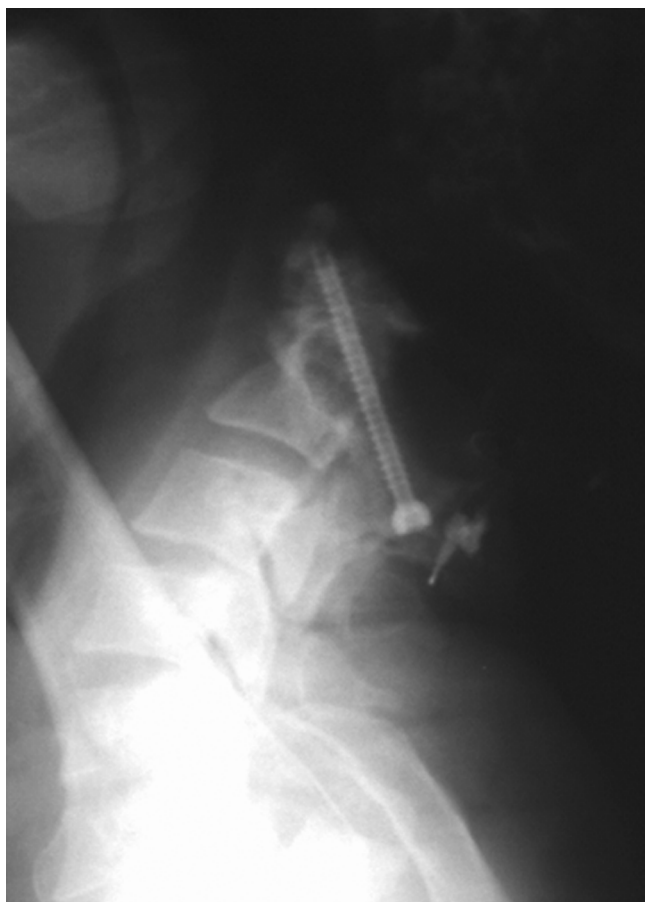

Fig. 3-A

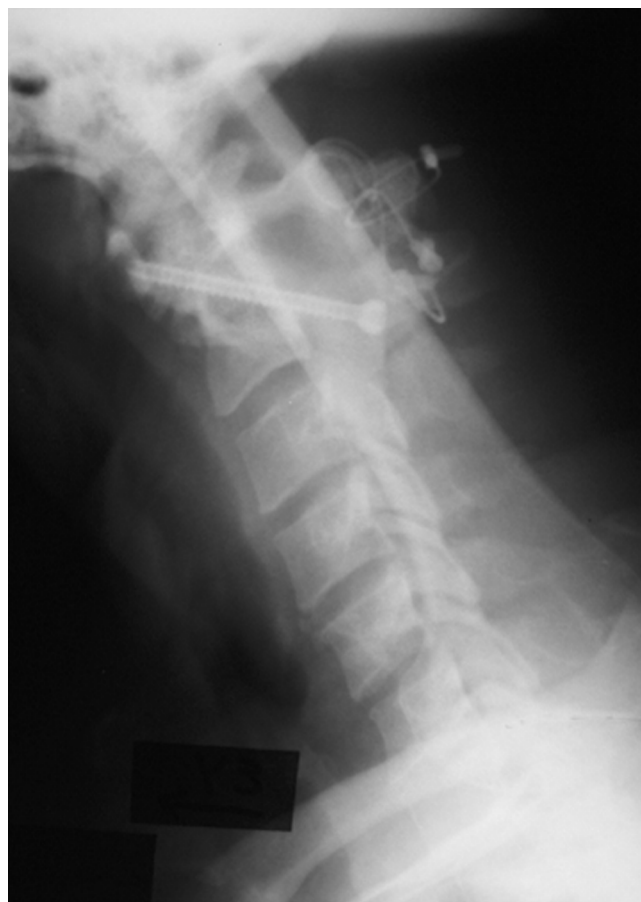

Fig. 3-B

Lateral extension (Fig. 3-A) and flexion (Fig. 3-B) plain radiographs made at the time of the four-year follow-up, demonstrating a solid C1-C2 fusion.

tures reported by van Holsbeeck et al.¹⁷, and 100% in a series of fifteen patients reported by Maiman and Larson¹⁸. In a case-control study of thirty-three patients with a type-II dens fracture treated with halo immobilization, patients older than fifty years of age were found to be at a significantly increased risk for failure of treatment with halo immobilization ($p = 0.002$)¹⁹. A retrospective review of 229 C2 fractures by Hadley et al. revealed that the rate of nonunion of acute type-II fractures is highest in patients older than sixty years of age with ≥ 6 mm of displacement⁴. The nonunion rate for the eighty-seven type-II dens fractures in that study was 28%. Several factors limit the ability to extrapolate the actual nonunion rate of dens fractures from the literature; these include a lack of uniformity with regard to sample sizes, inclusion and exclusion criteria, radiographic methods, criteria for identification of nonunion, and methods of external immobilization.

The case of our patient is unique because of the long interval between the injury and presentation of the myelopathy, the degree of progressive myelopathy developing almost forty years after the initial injury, the degree of displacement without additional trauma, and the patient's complete recovery. With careful diagnostic evaluation and thoughtful operative planning for stabilization of the injury, the patient had full resolution of

the myelopathy and was able to return to normal activities of daily living without restriction. Late-onset myelopathy has rarely been described in the literature^{1,2}. The asymptomatic interval of approximately forty years until the onset of the myelopathy secondary to the pseudarthrosis in our patient underscores the risks of nonoperative management as well as the potential for late neurologic compromise. ■

Jonas R. Rudzki, MD, MS

Lawrence G. Lenke, MD

Kathy Blanke, RN

K. Daniel Riew, MD

Department of Orthopaedic Surgery, Washington University School of Medicine, One Barnes-Jewish Hospital Plaza, Suite 11300, West Pavilion, St. Louis, MO 63110. E-mail address for L.G. Lenke: lenkel@msnotes.wustl.edu

The authors did not receive grants or outside funding in support of their research or preparation of this manuscript. They did not receive payments or other benefits or a commitment or agreement to provide such benefits from a commercial entity. No commercial entity paid or directed, or agreed to pay or direct, any benefits to any research fund, foundation, educational institution, or other charitable or nonprofit organization with which the authors are affiliated or associated.

References

1. **Paradis GR, Janes JM.** Posttraumatic atlantoaxial instability: the fate of the odontoid process fracture in 46 cases. *J Trauma.* 1973;13:359-67.
2. **Crockard HA, Heilman AE, Stevens JM.** Progressive myelopathy secondary to odontoid fractures: clinical, radiological, and surgical features. *J Neurosurg.* 1993;78:579-86.
3. **Anderson LD, D'Alonzo RT.** Fractures of the odontoid process of the axis. *J Bone Joint Surg Am.* 1974;56:1663-74.
4. **Hadley MN, Dickman CA, Browner CM, Sonntag VK.** Acute axis-fractures: a review of 229 cases. *J Neurosurg.* 1989;71:642-7.
5. **Puttlitz CM, Goel VK, Clark CR, Traynelis VC.** Pathomechanisms of failures of the odontoid. *Spine.* 2000;25:2868-76.
6. **Bucholz RW, Burkhead WZ, Graham W, Petty C.** Occult cervical spine injuries in fatal traffic accidents. *J Trauma.* 1979;19:768-71.
7. **Huelke DF, O'Day J, Mendelsohn RA.** Cervical injuries suffered in automobile crashes. *J Neurosurg.* 1981;54:316-22.
8. **Nachemson A.** Fracture of the odontoid process of the axis: a clinical study based on 26 cases. *Acta Orthop Scand.* 1960;29:185-217.
9. **Benzel EC, Hart BL, Ball PA, Baldwin NG, Orrison WW, Espinosa M.** Fractures of the C-2 vertebral body. *J Neurosurg.* 1994;81:206-12.
10. **Clark CR, White AA 3rd.** Fractures of the dens. A multicenter study. *J Bone Joint Surg Am.* 1985;67:1340-8.
11. **Schatzker J, Rorabeck CH, Waddell JP.** Fractures of the dens (odontoid process). An analysis of thirty-seven cases. *J Bone Joint Surg Br.* 1971;53:392-405.
12. **Alker GJ Jr, Oh YS, Leslie EV.** High cervical spine and craniocervical junction injuries in fatal traffic accidents: a radiological study. *Orthop Clin North Am.* 1978;9:1003-10.
13. **Althoff B.** Fracture of the odontoid process. An experimental and clinical study. *Acta Orthop Scand Suppl.* 1979;177:1-95.
14. **Mouradian WH, Fietti VG Jr, Cochran GV, Fielding JW, Young J.** Fractures of the odontoid: a laboratory and clinical study of mechanisms. *Orthop Clin North Am.* 1978;8:985-1001.
15. **Amyes EW, Anderson FM.** Fracture of the odontoid process. Report of sixty-three cases. *Arch Surg.* 1956;72:377-93.
16. **Seybold EA, Bayley JC.** Functional outcome of surgically and conservatively managed dens fractures. *Spine.* 1998;23:1837-46.
17. **van Holsbeeck E, Stoffelen D, Fabry G.** Fractures of the odontoid process. Conservative and operative treatment. Prognostic factors. *Acta Orthop Belg.* 1993;59:17-21.
18. **Maiman DJ, Larson SJ.** Management of odontoid fractures. *Neurosurgery.* 1982;11:471-6.
19. **Lennarson PJ, Mostafavi H, Traynelis VC, Walters BC.** Management of type II dens fractures: a case-control study. *Spine.* 2000;25:1234-7.