

# Arthroscopic Findings Following Traumatic Hip Dislocation in 14 Professional Athletes

Marc J. Philippon, M.D., Dave A. Kuppersmith, B.S., Andrew B. Wolff, M.D., and Karen K. Briggs, M.P.H.

---

**Purpose:** The purpose of this study was to investigate intra-articular hip joint pathologies in professional athletes who sustained dislocation and were treated with hip arthroscopy. **Methods:** Between August 23, 2000, and September 15, 2006, 14 professional athletes (12 male and 2 female) sustained a nonfracture traumatic hip dislocation during active competition and were treated by a single surgeon. A retrospective chart review of this cohort was done to report the intra-articular hip pathologies identified at the time of arthroscopy. **Results:** The average time from dislocation to relocation was 3.56 hours. The mean time from dislocation to surgery was 125 days (range, 0 to 556 days). The average age at the time of arthroscopy was 30.5 years (range, 16 to 46 years). All patients had labral tears. All patients had chondral defects. Two had isolated femoral head chondral defects, 6 had isolated acetabular chondral defects, and 6 had chondral defects on both surfaces. Eleven patients had loose osteochondral fragments. Eleven patients had partial or complete tears of the ligamentum teres. Nine patients had evidence of femoroacetabular impingement; 4 had isolated cam lesions, 1 had an isolated pincer lesion on the acetabular rim, and 4 patients had mixed type pathology. Two patients had capsulolabral adhesions. Two patients had a capsular tear. Additionally, 3 patients underwent intraoperative evaluation of the lateral epiphyseal vessels with Doppler imaging to confirm good blood flow to the femoral head with consistent pulse. **Conclusions:** The results of this study show that traumatic dislocation is accompanied by a variety of intra-articular hip joint pathologies, the most common being labral, chondral, intra-articular loose fragments, and disruption of the ligamentum teres. **Level of Evidence:** Level IV, diagnostic case study. **Key Words:** Dislocation—Femoroacetabular impingement—Hip arthroscopy—Professional athletes.

---

**F**orceful traumatic events in many sports can cause the hip joint to dislocate (Figs 1 and 2). These dislocations are often accompanied by a fracture requiring surgical intervention. In addition, avascular necrosis of the femoral head following hip dislocation is a serious potential complication that must not be

overlooked. When no fracture is present, nonoperative treatment is the most widely accepted practice. However, athletes who sustain dislocation frequently continue to have persistent disabling hip pain, and are unable to participate at the professional level; for these patients, nonoperative treatment is not an acceptable option.

Hip pain can be the result of intra-articular pathology that can potentially be a source for early degeneration and progression to osteoarthritis. With the increasing popularity of hip arthroscopy, the ability to address these intra-articular pathologies arthroscopically has become a feasible alternative to nonoperative management.

Recent studies have reported promising outcomes in professional athletes who undergo hip arthroscopy for the treatment of femoroacetabular impingement (FAI)

---

*From the Steadman Hawkins Research Foundation, Vail, Colorado, U.S.A.*

*The authors have received something of value from Smith and Nephew, Andover, Massachusetts.*

*Received June 20, 2008; accepted September 10, 2008.*

*Address correspondence and reprint requests to Marc J. Philippon, M.D., Steadman Hawkins Research Foundation, Attn: Clinical Research, 181 W Meadow Dr, Ste 1000, Vail, CO 81657, U.S.A. E-mail: karen.briggs@shsmf.org*

*© 2009 by the Arthroscopy Association of North America*

*0749-8063/09/2502-8349\$36.00/0*

*doi:10.1016/j.arthro.2008.09.013*

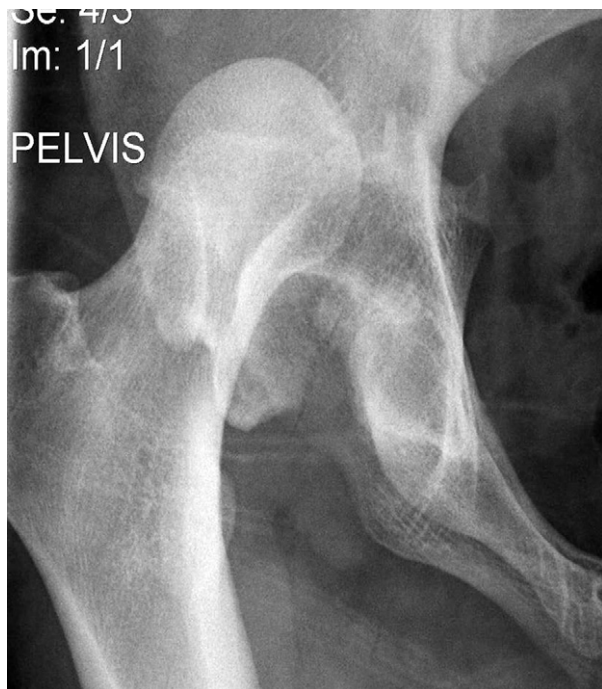

FIGURE 1. Anteroposterior pelvic radiograph showing hip dislocation following a traumatic injury.

and associated pathologies.<sup>1</sup> However, there is limited literature discussing the use of arthroscopy for the treatment of hip pain following traumatic hip dislocation.<sup>2,3</sup> The purpose of this study was to investigate the intra-articular hip joint pathologies identified at hip arthroscopy in professional athletes who sustained forceful traumatic dislocation. We hypothesized that patients would most commonly experience labral tears and chondral pathology following traumatic hip dislocation.

## METHODS

Between August 23, 2000, and September 15, 2006, 14 professional athletes sustained a traumatic hip dislocation during active competition. Inclusion criteria were professional athletes who sustained traumatic hip dislocation and underwent subsequent hip arthroscopy. Patients were excluded if they were not professional athletes. Two athletes spontaneously reduced on the field, 10 were actively reduced on the sidelines, and 2 were reduced in the emergency room. A retrospective chart review of this cohort was performed to report the intra-articular hip joint pathologies. All 14 athletes presented to the senior author (M.J.P.), following reduction, for evaluation of hip pathology and

persistent pain. All athletes were unable to play their sport at time of evaluation for arthroscopy.

## Radiographic Evaluation

Athletes underwent anteroposterior (AP) pelvis and cross table lateral plain film radiographs and magnetic resonance imaging (MRI) to evaluate for hip joint pathologies.<sup>1,4</sup> Routine AP pelvis radiographs were taken to evaluate for fractures, residual subluxation, loose bodies, and to assess center edge angle for the presence of dysplasia or pincer type impingement (cross-over sign or coxa profunda, protusion)<sup>4-6</sup> and joint space narrowing. Cross table lateral radiographs were obtained to identify a cam lesion<sup>7,8</sup> and MRI scans were obtained to evaluate chondral and labral pathology.

## Arthroscopic Technique

The modified supine approach to hip arthroscopy was used with 2 portals (anterior and anterolateral). The hip was placed in 10° of flexion and 15° of internal rotation, with approximately 50 lbs of traction applied to create between 7 and 10 mm of joint space. A complete diagnostic arthroscopic examination was performed to identify intra-articular pathology.<sup>4</sup>

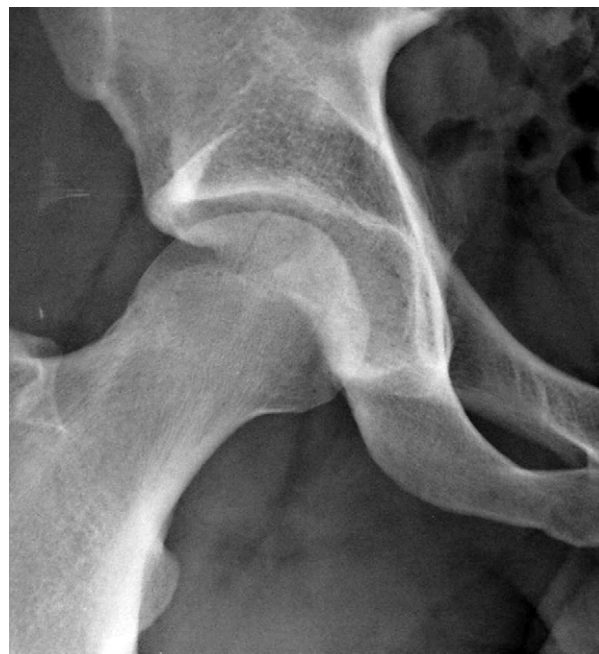

FIGURE 2. Anteroposterior pelvic radiograph following reduction.

**TABLE 1.** Patient Demographics

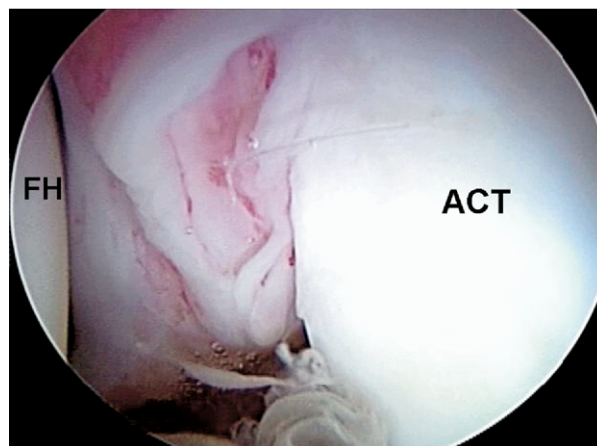
Patient No.	Age (yr)	Sport	Time to Relocation (hr)	Time from Injury to Arthroscopy (d)
1	18	Biking	2	218
2	20	Rugby	12	131
3	26	Football	5	122
4	29	Football	3	100
5	22	Dancing	2	3
6	16	Football	6	92
7	30	Football	4	0
8	16	Track	0	198
9	18	Basketball	2	45
10	17	Biking	4	63
11	22	Football	0	24
12	20	Biking	4	18
13	32	Skiing	2	138
14	46	Hockey	4	556

### Postoperative Rehabilitation

The physical therapy protocol following hip arthroscopy was rigorous.<sup>9</sup> Patients were partial weight bearing with crutch assistance for 2 weeks. Stationary bicycle exercises with no resistance commence at 1 day postoperatively. The focus on early range of motion is thought to prevent the formation of adhesions.

### RESULTS

Eighty-five percent of this cohort were posterior dislocations and 15% were anterior dislocations. The mean time from dislocation to reduction was 3.56



**FIGURE 3.** Intraoperative view of an acetabular labral tear before undergoing labral repair. (ACT, acetabulum; FH, femoral head.)

hours. The mean time from dislocation to surgery was 125 days (range, 0 to 556 days). The average age at the time of arthroscopy was 30.5 years (range, 16 to 46 yrs; Table 1).

### Intra-articular Pathology

The intra-articular hip pathology found at the time of arthroscopy can be found in Table 2. Labral (Fig 3) and chondral pathology was the most common finding at arthroscopy. Chondral defects were found isolated to the femoral head (Fig 4), isolated to the acetabulum, or a mixture of both surfaces. Intra-articular loose fragments and ligamentum teres pathology, either par-

**TABLE 2.** Hip Pathologies Identified at Arthroscopy

Patient No.	Months*	Spontaneous Reduction	Hip Pathology Identified at Arthroscopy						
			Labral	Adhesions	Capsule Tear	Ligamentum Teres	Cam	Pincer	Chondral Defect
1	7.3	N	Y	—	—	Y	Y	Y	Y
2	4.4	N	Y	—	Y	Y	Y	—	Y
3	4.0	N	Y	—	—	—	—	—	Y
4	3.3	N	Y	—	—	Y	—	—	Y
5	0.1	N	Y	—	—	Y	—	—	Y
6	3.1	N	Y	—	—	Y	—	—	Y
7	0	N	Y	—	—	Y	—	—	Y
8	6.6	Y	Y	—	—	—	—	Y	Y
9	1.5	N	Y	Y	Y	Y	Y	—	Y
10	2.1	N	Y	—	—	Y	Y	Y	Y
11	0.8	Y	Y	—	—	Y	Y	Y	Y
12	0.6	N	Y	—	—	Y	Y	—	Y
13	4.6	N	Y	Y	—	Y	Y	—	Y
14	18.5	N	Y	—	—	Y	Y	Y	Y

\*Months from dislocation to hip arthroscopy.

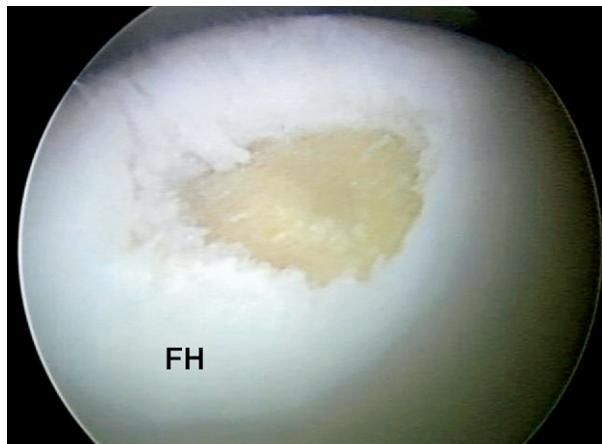


FIGURE 4. Femoral head grade IV chondral defect that underwent subsequent microfracture. (FH, femoral head.)

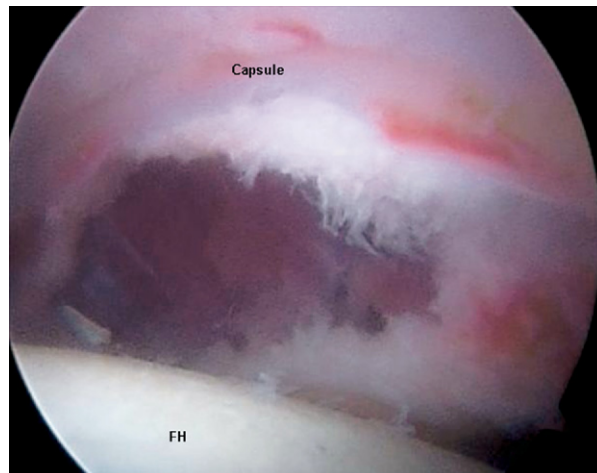


FIGURE 5. Torn capsule following a traumatic injury which underwent suture repair. (FH, femoral head.)

tial or complete rupture, were additional common findings at arthroscopy following dislocation in the professional athlete. FAI pathology consisted of isolated cam lesions, isolated pincer lesions, and mixed type FAI were all found in the majority of patients following dislocation.

Patients with cam or mixed lesions of the femoral head–neck junction had a judicious osteoplasty in order to restore appropriate head–neck offset to prevent impingement (Table 3). Two patients had capsulolabral adhesions, which were released, and 2 had a torn capsule (Fig 5) necessitating repair. Twenty-two percent had no arthritic changes, 36% had mild ar-

thritic changes, 21% had medium changes, and 21% had a high degree of arthrosis. Thirty-six percent had acetabular rim fractures. None of the acetabular rim fractures (Fig 6) constituted greater than 20% of the posterior wall for posterior dislocations or 20% of the anterior wall for anterior dislocations. Most were small fragments (<1 cm wide) that were excised without consequence. None were amenable to fixation, nor were the fragments a source of instability in any of the cohort.

All 14 athletes returned to full competitive professional sports after arthroscopic intervention for the

TABLE 3. Treatment of Hip Pathologies

Patient No.	Labral		LOA	Capsule Repair	Ligamentum Teres	FH Osteoplasty	ACT Rim Trimming	Microfracture	
	Repair	Debride			PD		Pincer	ACT	FH
1	Y	—	—	—	Y	Y	Y	Y	—
2	Y	—	—	Y	Y	Y	—	—	Y
3	—	Y	—	—	—	—	—	Y	—
4	—	Y	—	—	Y	—	—	—	Y
5	Y	—	—	—	Y	—	—	—	—
6	—	Y	—	—	Y	—	—	—	—
7	—	Y	—	—	Y	—	—	—	—
8	—	Y	—	—	—	—	Y	Y	Y
9	Y	—	Y	Y	Y	Y	—	Y	—
10	Y	—	—	—	Y	Y	Y	—	—
11	—	Y	—	—	Y	Y	Y	—	Y
12	—	Y	—	—	Y	Y	—	—	Y
13	—	Y	Y	—	Y	Y	—	—	—
14	Y	—	—	—	Y	Y	Y	Y	—

Abbreviations: ACT, acetabulum; FH, femoral head; LOA, lysis of adhesions; PD, partial debridement.



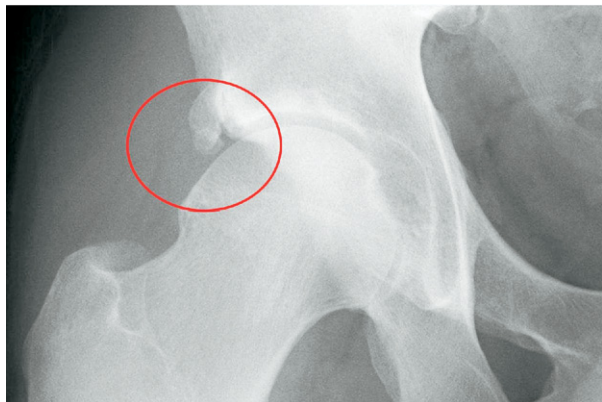


FIGURE 6. Radiographic evidence of an acetabular rim fracture.

treatment of debilitating hip pain following traumatic dislocation.

## DISCUSSION

This study showed that the most common intra-articular hip pathologies found at the time of arthroscopy following hip dislocation were labral tears, chondral defects, and loose bodies. Because the hip is a constrained joint, hip dislocation most commonly occurs following a high-energy injury. In the general population, hip dislocation is commonly associated with acetabular fractures, femoral head and neck fractures, and significant injuries to other areas of the affected limb and indeed the body. While patients with fracture-dislocations of the hip joint have been shown to fare worse than those with pure dislocation without fracture, up to half of patients with pure dislocations still have unsatisfactory results.<sup>10-13</sup> The most common long-term sequelae of hip dislocation leading to disability are post-traumatic arthrosis and osteonecrosis, with time to onset of 2 to 5 years after initial injury.<sup>13</sup> The incidence of osteonecrosis of the femoral head following hip dislocation has been reported to be between 6% and 40%.<sup>14</sup> Early evaluation and treatment has been advocated as the best prevention for osteonecrosis. In this study, 1 patient had arthroscopy on the day of dislocation, following an unsuccessful attempt at closed reduction at the stadium. The time from dislocation to arthroscopy was varied. If patients had a successful closed reduction, most underwent a physical therapy protocol. If they could not return to their sport, they were referred for arthroscopic evaluation.

Because of the paucity of reports in the literature, the incidence of hip dislocation in professional athletes is unclear.<sup>15-19</sup> Giza et al.<sup>18</sup> discussed the relatively uncommon occurrence of fracture dislocation among professional soccer players. Their group had experience with treating 2 professional soccer players and concluded that prompt reduction and fixation are important to produce a stable and congruent joint.

Moorman et al.<sup>19</sup> reported on traumatic posterior hip subluxation in American football players. They found that over a 9-year period, they saw 8 professional football players who traumatically dislocated and were treated. The most common mechanism of injury in their cohort was falling on a flexed, adducted hip. Their patients had limited hip range of motion and pain. Two of the athletes underwent hip aspiration, and 6 were treated with nonoperative crutch assistance for 6 weeks.<sup>19</sup> This study also showed disruption of the iliofemoral ligament, which the authors presumed was caused by a transient episode of posterior subluxation.<sup>19</sup> In contrast, athletes with dislocations had tears of the ligamentum teres and acetabular rim fractures. This may be indicative of the different injury patterns seen in low- and high-energy dislocations.

These reports suggest that a minority of professional athletes who sustain a hip dislocation return to the same level of play. While the end result of a substantially increased rate of arthrosis is well recognized, the etiology of this is unclear. Goulet and Levin<sup>20</sup> speculate that this is a result of articular cartilage damage and chondrocyte death initiated at the time of impact.

Professional athletes with hip dislocation represent a distinct population demonstrating less tolerance for loss of hip function. Restoration of function is paramount for these individuals to maintain their livelihood. As such, these patients are more likely to present for treatment earlier than patients who do not rely on a high level of hip function to make a living. Therefore, the reasons we undertook this study were twofold: (1) To describe the pathology encountered in a professional athlete's hip following hip dislocation in order to elucidate the causes of disability most common in this population, and (2) to describe the relatively early findings in a hip following dislocation.

This study was limited by several factors. This study was a retrospective case series study with all of the limitations that entails. The cohort is not uniform, because patients from different sports with different mechanisms of injury were included. Also, it is unclear that the findings in the hips of patients who sustained relatively low-energy dislocations in athlet-

ics can be generalized to the more common scenario of high-energy trauma situations. Furthermore, we truly do not know if the dislocation was the sole cause of these findings for each patient. There very well may have been pre-existing underlying issues including femoroacetabular and chondrolabral dysfunction.

Nevertheless, we believe that important information can be gleaned from this cohort of patients. All of the patients in this study had labral tears and chondral defects, and 11 of the 14 had loose osteochondral bodies found at the time of arthroscopy. While these findings may have contributed to their preoperative symptoms, they have all been implicated in the development of arthritis.<sup>8</sup> It is possible and indeed likely that some of the patients had arthritis before hip dislocation—especially in light of the fact that 9 of the 14 had evidence of FAI before surgery.

### CONCLUSIONS

The results of this study show that traumatic dislocation is accompanied by a variety of intra-articular hip joint pathologies, the most common being labral, chondral, and intra-articular loose fragments and disruption of the ligamentum teres.

### REFERENCES

1. Philippon MJ, Schenker M, Briggs KK, Koppersmith DA. Femoroacetabular impingement in 45 professional athletes: Associated pathologies and return to sport following arthroscopic decompression. *Knee Surg Sports Traumatol Arthrosc* 2007;15:908-914.
2. Kashiwagi N, Suzuki S, Seto Y. Arthroscopic treatment for traumatic hip dislocation with vulsion fracture of the ligamentum teres. *Arthroscopy* 2001;17:67-69.
3. Mullis BH, Dahners LE. Hip arthroscopy to remove loose bodies after traumatic dislocation. *J Orthop Trauma* 2006;20:22-26.
4. Philippon MJ, Stubbs AJ, Schenker ML, Maxwell RB, Ganz R, Leunig M. Arthroscopic management of femoroacetabular impingement: Osteoplasty technique and literature review. *Am J Sports Med* 2007;35:1571-1580.
5. Reynolds D, Lucas J, Klaue K. Retroversion of the acetabulum: A cause of hip pain. *J Bone Joint Surg Br* 1999;81:281-288.
6. Klaue K, Durnin CW, Ganz R. The acetabular rim syndrome: A clinical presentation of dysplasia of the hip. *J Bone Joint Surg Br* 1991;73:423-429.
7. Notzli HP, Wyss TF, Stoecklin CH, Schmid MR, Treiber K, Hodler J. The contour of the femoral head-neck junction as a predictor for the risk of anterior impingement. *J Bone Joint Surg Br* 2002;84:556-560.
8. Ganz R, Parvizi J, Beck M, Leunig M, Notzli H, Siebenrock KA. Femoroacetabular impingement: A cause for osteoarthritis of the hip. *Clin Orthop Relat Res* 2003;417:112-120.
9. Wahoff M, Briggs KK, Philippon MJ. Hip arthroscopy rehabilitation: Evidence-based practice. In: Kibler WB, ed. *Orthopaedic knowledge update: Sports medicine 4*. Rosemont, IL: American Academy of Orthopaedic Surgeons (in press).
10. Upadhyay SS, Moulton A. The long-term results of traumatic posterior dislocation of the hip. *J Bone Joint Surg Br* 1981;63:548-551.
11. Upadhyay SS, Moulton A, Srikrishnamurthy K. An analysis of the late effects of traumatic posterior dislocation of the hip without fractures. *J Bone Joint Surg Br* 1983;65:150-152.
12. Yang RS, Tsuang YH, Hang YS, Liu TK. Traumatic dislocation of the hip. *Clin Orthop Relat Res* 1991;265:218-227.
13. Dreinhofer KE, Schwarzkopf SR, Haas NP, Tscherne H. Isolated traumatic dislocation of the hip. Long term results in 50 patients. *J Bone Joint Surg Br* 1994;76:6-12.
14. Rodriguez-Merchan EC. Osteonecrosis of the femoral head after traumatic hip dislocation in the adult. *Clin Orthop Relat Res* 2000;377:68-77.
15. Pallia CS, Scott RE, Chao DJ. Traumatic hip dislocation in athletes. *Curr Sports Med Rep* 2002;1:338-345.
16. Sahin V, Karakş ES, Aksu S, Atlıhan D, Turk CY, Halici M. Traumatic dislocation and fracture-dislocation of the hip: A long-term follow-up study. *J Trauma* 2003;54:520-529.
17. Yates C, Bandy WD, Blasler RD. Traumatic dislocation of the hip in a high school football player. *Phys Ther* 2008;88:780-788.
18. Giza E, Mithöfer K, Matthews H, Vrahas M. Hip fracture-dislocation in football: A report of two cases and review of the literature. *Br J Sports Med* 2004;38:E17.
19. Moorman CT 3rd, Warren RF, Hershman EB, et al. Traumatic posterior hip subluxation in American football. *J Bone Joint Surg Am* 2003;85:1190-1196.
20. Goulet JA, Levin PE. Hip dislocations. In: Browner BD, Jupiter JB, Levine AM, Trafton PG, eds. *Skeletal trauma: Basic science, management, and reconstruction*. Ed 3. Philadelphia: Saunders, 2003;1657-1669.